

MACRO AND MICROSCOPIC EXAMINATION OF OVARIAN PATHOLOGIES IN  
ABATTOIR SAMPLES OF BUFFALO OF AGRA REGION, UTTAR PRADESH, INDIA

Sushant Srivastava, Vijay Gautam, Pushkar Sharma, Saurabh Verma,  
Rajesh Kumar\* and Rabindra Kumar

Received: 31 July 2020

Accepted: 27 June 2023

**ABSTRACT**

The present study was aimed to assess the type and prevalence of gross and microscopic lesions in ovaries of buffaloes obtained from abattoir. The prevalence of abnormalities of uterus were highest (17.02%; 181 samples) followed by ovaries (7.98%; 85 samples) among ten different types of anatomic abnormalities with overall prevalence of 29.83% (317/1062). Among the 85 ovarian lesions, the most observed lesions were sub active ovaries (34.11%), par ovarian cyst (20%), ovarobursal adhesion (20%), and cystic ovary (20%).

To decipher ovarian hypofunction and other abnormalities, per-rectal examination and transrectal ultrasonography is used with variable degree of success to diagnose unilateral small sized pathological affections. In addition to visualize reproductive organs, ultrasonography also helpful to assess morphotype, localization, number, and size as well as shape of internal formations. The project sought to procure basic data for further investigation that would enable providing scientific support for methods to boost production through full utilization of the bubaline genetic potential.

**Keywords:** *Bubalus bubalis*, buffaloes, abattoir, examination, pathology, ovary

**INTRODUCTION**

Success of any livestock development programs depend upon proper function of reproductive organs. One of the most important factors affecting an animal's entire lifetime performance is optimal fertility, which in turns depend on anatomic and functional soundness of genital organs. Different physiological and pathological affections affect the function status of organ. Various pathological lesions *viz.* congenital anatomic defects, tumors, cysts, and pathological disorders etc. alter anatomic and functional soundness of genital organs. Furthermore, Sane *et al.* (1964), opined that precise understanding of same is necessary for full exploitation of fertility potential of buffaloes. Estrus cycle failure is the most common and costly infertility problem of buffaloes because of high incidence and resulting calf crop and production losses (Luktuke and Sharma, 1979). Singh *et al.* (1979) reported 17.4% incidence of anestrus in buffaloes up to 45 to 50 days postpartum. The reproductive disorder

is a major cause of economic losses in buffalo production, as they result in sub-fertility, shorter life-time production, longer inter-calving interval, and higher medical costs.

The prevalence of infertility has been estimated up to 15 to 20% in cattle and buffaloes in India, the majority of which is due to acyclicity, suboestrus and cyclic non-breeder (Sreemannarayana and Rao, 1997; Butani *et al.*, 2008; Butani *et al.*, 2009; Kumar *et al.*, 2008; Kumar *et al.*, 2009; Kumar *et al.*, 2010; Kumar *et al.*, 2011). In majority of cases the repeat breeding syndrome is ascribed to dietary deficiencies, reproductive tract anomalies, hormonal asynchrony (Bage *et al.*, 1997), delayed ovulation, inadequate luteal function and other managemental factors. Water buffalo have extremely high rates of genital tract anomalies, which range from 47.9 to 67.3% (Alwan *et al.*, 2001; Al-Fahad *et al.*, 2004; Azawi *et al.*, 2008).

Number of abattoir surveys of buffalo genitalia had been carried out to evaluate the prevalence of macroscopic and microscopic pathologies (Shalash, 1958; Vale *et al.*, 1981; Ganorkar and Paikne, 1994; Ghora *et al.*, 1996; Tafti and Darahshiri, 2000; Sujata, 2000). Luktuke *et al.* (1979) observed a higher (56.0% vs 36%) incidence of anoestrous in buffalo heifers than cow heifers.

The prospects for gynecological examinations in live animals were strengthened with the availability of transrectal ultrasonography. Ultrasonography was initially employed in veterinary medicine primarily to evaluate the normal anatomical characteristics of the reproductive tract (Pierson and Ginther, 1984). Its use spread quickly as a trustworthy instrument for ovarian follicle and corpora lutea assessment as well as pregnancy identification. Pathological

conditions were typically discovered accidentally and were different from physiological traits. Now, interest has been focused on using ultrasonography to decipher pathological uterine and ovarian diseases (Fissore *et al.*, 1986; Kahn and Leidl, 1989). Real-time ultrasonography has become extremely popular recently in veterinary and animal science as a research and diagnostic tool (Rajamahendran *et al.*, 1994). Many of the ultrasonographic features of reproductive pathologies have been clearly described for cattle (Reeves *et al.*, 1984; Pierson and Ginther, 1988; Fissore *et al.*, 1986; Ali and Abdel-Razek, 2002; DesCoteaux *et al.*, 2006; Des Coteaux *et al.*, 2009).

## MATERIALS AND METHODS

The experiment was carried out on 1062 slaughterhouse derived buffalo genitalia from Municipality abattoir, Kuberpur. The reproductive organs with gross anatomic, microscopic abnormalities were taken under study. Abattoir visits were arranged once a week for sample collection and the other days of the weeks were utilized for processing of samples. Post-slaughter, the reproductive organs were taken out and individually examined and palpated for any gross pathological diseases and distribution of and disorders prior to any incision (Garcia, 1998). The lesions were examined for size, shape, color, consistency, and texture. Moreover, ovaries were examined in the presence of physiological or pathological structures (Kunbhar *et al.*, 2003).

In order to prevent tissue damage, tissues with lesions were transferred to the lab in an icebox with due care. Afterwards, a histological inspection as well as a bacteriological investigation was carried out in laboratory. To stabilize tissues

and prevent decomposition, the portion tissue's lesion was cut into two or three cm-long pieces and placed in 10% buffered formalin. Ultrasonographic examination of genitalia (Figure 1) was performed using 5/7.5 MHz linear probe as method elucidated by Saini *et al.* (2008); Sevimli *et al.* (2012).

## RESULTS AND DISCUSSIONS

Out of 1062 abattoir derived samples, 317 (29.83%) were found positive for abnormalities. Out of ten different types of abnormalities recorded, abnormalities of uterus were higher as compared to (17.02% vs 7.98%) ovarian abnormalities (Table 1 and 2). Similar observations were also reported by Kodagali and Kerur (1968). Furthermore, higher and lower prevalence were reported in many previous studies (Tomar *et al.*, 2002; Mittal *et al.*, 2010; Azawi and Ali, 2011; Amin, 2016; Pesantez *et al.*, 2016). The difference in the incidence might be due to variation in the breed, region, management practices and provision of health cover etc. In the present study microscopic lesions were recorded in one or more organs though they were apparently normal. The findings suggest that trans-rectal palpation may not diagnose all cases of genital abnormalities.

The second highest abnormalities detected were associated with ovaries (7.98%). Among 85 ovarian lesions, the most observed lesions were sub active ovaries (34.11%), par ovarian cyst (20%), ovarobursal adhesion (20%), and cystic ovary (20%) (Table 2). The present findings agreed with many previous studies (Shokeir, 1958; Amin, 2016). Whereas, Luktuke *et al.*, 1973; Azawi *et al.*, 2011; Hasan (2015) reported a higher incidence of ovarian disease, however lower values were recorded by Ribeiro (2016).

Many workers opined that increasing incidence ovarian abnormalities were attributed to senile changes, climatic stress, malnutrition, and infections, thus increasing the possibility of development of endocrinological asynchrony and subsequently varied type of lesions (Bhattacharya *et al.*, 1954; Luktuke *et al.*, 1973; Chauhan and Singh, 1979). Any disturbance in the functional activity or disorders of ovary would adversely affect the various processes of reproduction in different phases and as a result, pregnancy even if established might not end normally (Luktuke *et al.*, 1973). Khan (1991) stated that the ovary is the site of production of ova considered as an essential organ of reproduction of females. Diseases of ovaries could cause malfunctioning of reproductive organs leading to infertility and sterility. Unlike macroscopic and microscopic examination, the ultrasonographic examination was better to detecting the genital abnormalities. Present observations were supported with previous worker (Saini *et al.*, 2008) and furthermore, reliability of ultrasonography was at par (above 85%) in diagnosing various genital tract abnormalities except for cervicitis and pyometra wherein sensitivity was low. Implementation of RT ultrasonography in veterinary medicine seems to be most efficient diagnostic aid for reproductive augmentation, as it is non-invasive, reliable and simple technique without untoward side effects (Terzano, 2012).

### Follicular cyst

Out of 1062 genitalia examined, 0.94% of genitalia exhibited follicular Cyst (seven on right ovary, three on left ovary). The follicular cysts are thin walled, extremely pale, fluid (sticky, watery and transparent) filled vesicles, range from 25 to 30 mm in diameter (Figure 1). The incidence was

close to the observation made by others (Saini *et al.*, 2008). On ultrasonographic examination, follicular cyst appeared as  $\geq 25$  mm sized, thin-walled ( $\leq 3$ mm) non-echogenic structure protruding over ovarian surface. Furthermore, the uterus was dark with no echogenic spots with greyish-black structure (Figure 2). These agree with findings published by Naoki, 2007.

Failure of LH induced ovulation results in development of follicular cysts (Ananda Raja, 2003). The hormonal imbalance causes varying degree of changes in genital tract (Dwivedi and Singh, 1975; Kumar 1981; Ghora, 1995; Ananda Raja, 2003). They also observed cystic dilation of endometrial glands. Heranjali *et al.* (1978); Janakiraman (1978) related cystic ovaries to high prolactin levels in serum which had a suppressing effect on follicular stimulating hormone and luteinizing hormone.

The follicular cysts had 1 to 2 extremely thin layers of granulosa cells lining them at the microscopic level. Granulosa cells occasionally had degenerative alterations, and theca cells and granulosa cells occasionally did as well. In all instances, no ovum was visible in a cystic lumen (Figure 3), and congested blood vessels were detected in the theca externa (Figure 4).

### Luteal cysts

In the right ovaries 7 cases (0.65%) of luteal cysts were recorded, which was smooth, round and thick walled (Figure 5). Moreover, none of the left ovaries exhibited luteal cysts. Rao and Rajya (1976) observed a much lower incidence of 0.12% whereas, Sharma *et al.* (1967b) observed a high incidence of 4.48% in she-buffaloes. Although luteinizing hormone was secreted in such cases probably the level was inadequate to cause ovulation (Jubb *et*

*al.*, 1992). In ultrasonographic examination, the luteal cysts were appeared as large sized ( $>25$  mm) thick walled ( $>3$  mm) follicle with anechoic central cavity (Figure 6).

### Embedded corpus leutum

Early CI and corpus luteum are shown in Figure 7 and 8. Embedded CL (Figure 9) and persistent CL were noticed in 7.05% of genitalia of buffaloes. A similar incident was as reported by Damodaran (1956). Unlike present observations, Sharma *et al.* (1967); Ingole *et al.* (2006) recorded a very greater incidence *i.e.*, 9.56%. Embedded CL was associated with subacute nonsuppurative endometritis in collected samples, whereas the persistent CL was observed in case of hydrometra or pyometra with the macerated foetus and was considered secondary to the inflammatory lesions in the genitalia (Damodaran, 1956). Embedded or persistent CL might be due to a lack of diminished secretion of luteolytic substances released by the severely inflamed uterus on the loss of foetus. Ghora (1995) reported that the continuous progesterone production of from embedded CL may result in prolonged anestrus.

### Parovarian cysts

Par ovarian cysts, a small (4 to 7 mm) and clear fluid filled structures, were observed in 17 (1.60%) cases in which ten were reported on the right and seven at left side. Paroophoron (caudal mesonephric tubules) and epoophoron (cranial mesonephric tubules) give rise the majority of parovarian cysts. On ultrasonographic examination, the parovarian cyst appears as round or oval shaped structure (1-5cm in diameter) with a central fluid-filled non-echogenic cavity attached to mesovarium (Figure 10 and 11).

### Ovarian hypoplasia

Ovarian hypoplasia was diagnosed in 22 (25.88%) buffalo genitalia. Grossly, the affected ovaries were smooth, oval shaped and very small (1.5 to 1.8 cm in length). They may be unilateral or bilateral in nature (Figure 12 and 13). In USG diagnosis, ovaries appeared as nonechogenic area (CL) in the ovarian stroma and small follicles (nonechogenic structures) (5 to 7 mm diameter).

The incidence in the current study was in accordance with the observation of Moogi (1978), however, many others reported a much higher prevalence up to 30.43%. The histological features were like those reported by others (Saini *et al.* (2008). Amin, (2016) It was associated with uterine atrophy in one case and trabecular form of the micro follicle and serous fibro papillary cystadenomatous structures in another case. The cause of ovarian inactivity in the buffaloes was probably due to the diminished release of gonadotrophic hormone from the adenohypophysis (Shokeir, 1958; Dwivedi and Singh, 1971).

Some researchers (El-sawaf and Schmidt, 1963; Dwivedi and Singh, 1971) stated that hypothyroidism probably due to high ambient temperature in buffalo was responsible for the summer sterility and suggested that hypothyroidism reduced the responsiveness of the ovary to the gonadotrophins. Ovarian inactivity in buffaloes with nutritional errors was due to the deficiency of Vitamin A, mineral, and trace elements in the ration (Dwivedi and Singh, 1971; Ghora, 1995). Anoestrus was noticed clinically in inactive ovarian condition (Heranjal *et al.*, 1978; Namboothiripad and Luktuke, 1978).

Kumar (1981) reported that in addition to nutritional deficiencies or hormonal imbalance, subclinical infections might be responsible for the development of subactive and inactive ovaries.

The inactive ovaries were the advanced stages of the subactive ovaries (Figure 14). He observed anovular cords / follicles in the affected ovaries. The associated changes in the tubular genitalia were endosalpingial epithelial hyperplasia, endometrial cystic glandular hyperplasia, and squamous cell metaplasia. Like present study, Youssef *et al.* (1991) also observed small, inactive uterine glands with thickening of the blood vessel wall.

### Ovario-bursal adhesions

Ovario-bursal adhesions were found in 17 (1.60%) genitalia. In the majority of cases right ovary was involved (12 vs 5) and fibrous network extending from mesosalpinx to half of the affected ovaries (Figure 15). Similarly, Ananda raja (2003) also reported that adhesions of ovaries with bursa, fallopian tube, and mesosalpinx were encountered in six cases (1.41%) (Figure 12). Studies from abattoir material by Ramamohanarao *et al.* (1965); Sharma *et al.* (1967); Bukhan (1970) revealed the incidence of bursal adhesion and encapsulation in 2.50, 8.59 and 7.17% of buffaloes respectively. Dwivedi and Singh (1971) observed 6.3% adhesions in female genital organs of 1,725 buffaloes. They formed varying degrees of severe adhesions to complete encapsulation at the tubo-ovarian region. Oshashi *et al.* (1984); Khanna *et al.* (1995) reported ovaro-bursal adhesions in buffaloes where strands of fibrous tissue attached to ovary formed complete encapsulation of ovaries and histologically tissue sections revealed diffuse mononuclear infiltration (Figure 16).

### Oophoritis

Oophoritis was found in 3 (3.52%) cases and all lesions were detected in the right-side ovary. The oophoritis might be due to systemic infectious diseases like brucellosis and tuberculosis,

Table 1. Prevalence and distribution of pathological condition of female genitalia of buffaloes (n=1062).

Sl. No.	Organ	Gross lesion	Percentage out of 1062 genitalia examined
1	Ovary	85	8.00
2	Fallopian tube	15	1.41
3	Uterus	181	17.04
4	Cervix	32	3.01
5	Vagina	4	0.37
	Total	317	29.83

Table 2. Prevalence and distribution of pathological condition of ovaries.

Sl. No.	Pathological condition	Genitalia with gross lesion	Distribution of right side	Left side	Percentage of total affected ovaries examined	Percentage out of 1062 genitalia examined
1	Oophoritis	3	3	0	3.52	0.28
2	Ovaro-bursal adhesion	17	12	5	20	1.60
3	Follicular cyst	10	7	3	11.76	0.94
4	Luteal cyst	7	7	0	8.2	0.65
5	Par ovarian cyst	17	10	7	20	1.60
6	Persistent corpus luteum	6	5	1	7.05	0.56
7	Haematoma	3	3	0	3.52	0.28
8	Ovarian hypoplasia	22	13	9	25.88	2.07
	Total	85	60	25		7.98

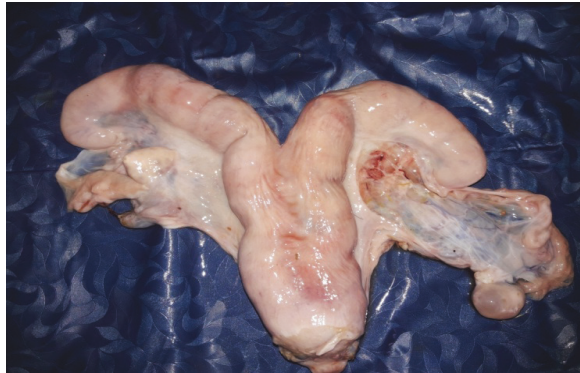

Figure 1. Follicular cyst.

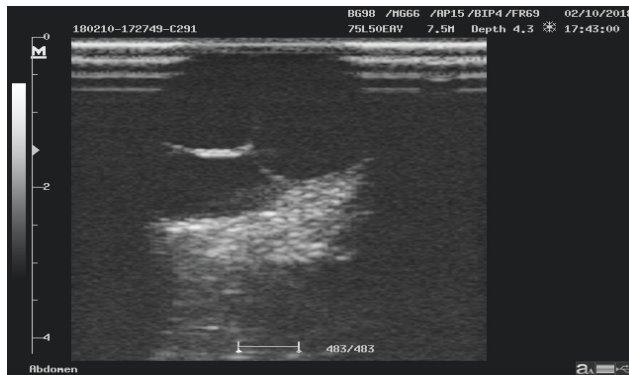

Figure 2. Ultrasonographic image of follicular cyst.

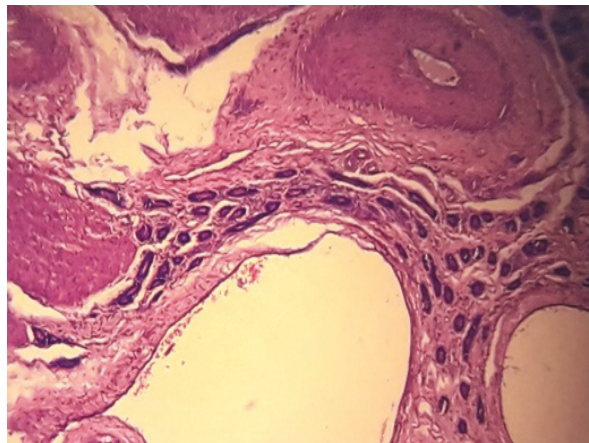


Figure 3. Follicular cyst without ovum (H&E).

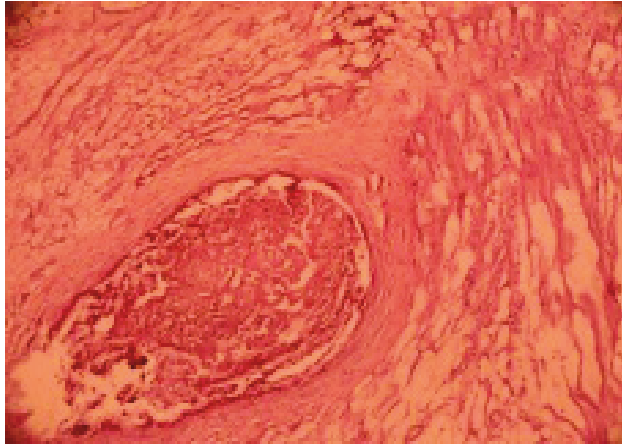


Figure 4. Follicular cyst theca externa with congested blood vessels (H&E).

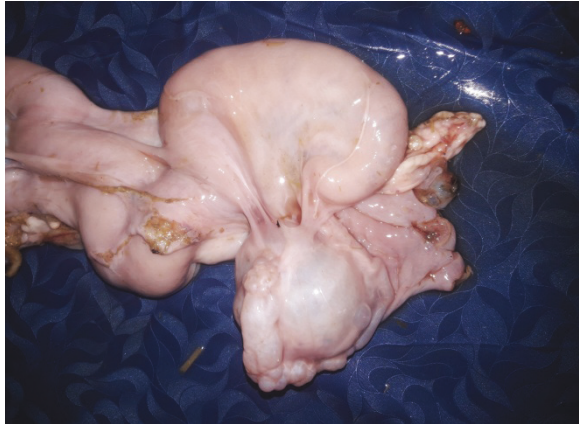

Figure 5. Luteal cyst.

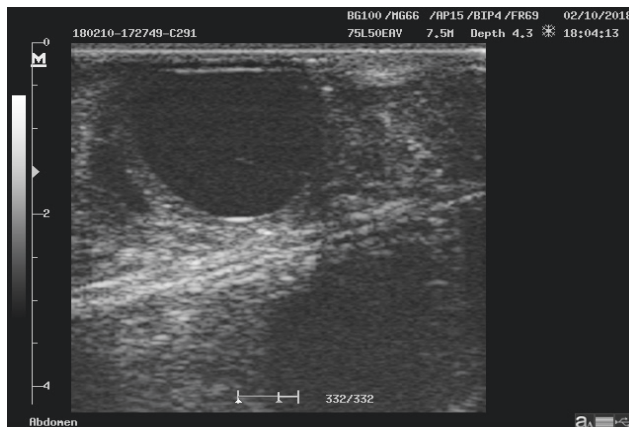


Figure 6. Ultrasonographic image of luteal cyst cyst.



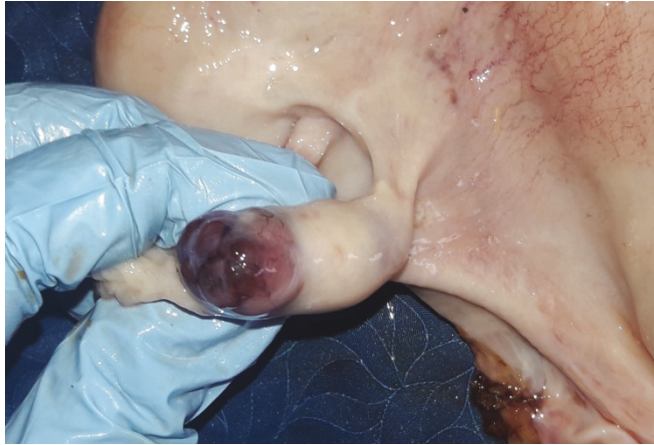

Figure 7. Early Corpus luteum.

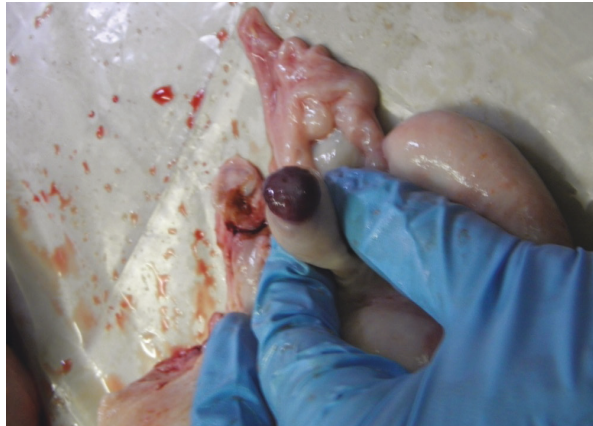

Figure 8. Corpus luteum.

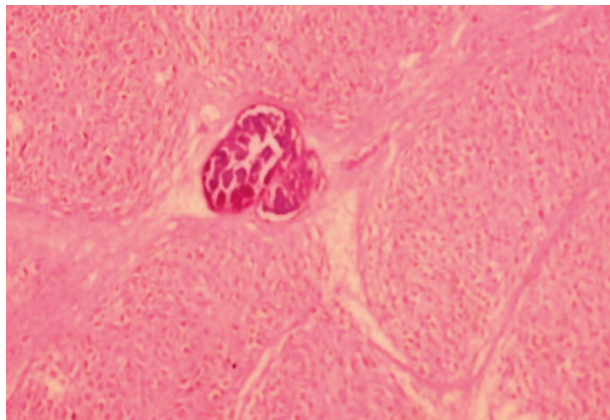


Figure 9. Embadded CL, fibrous septa divided normal leuteal tissue (H&E).

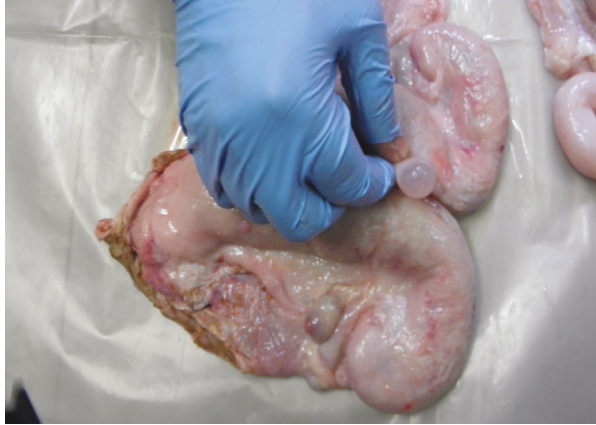

Figure 10. Parovarian cyst

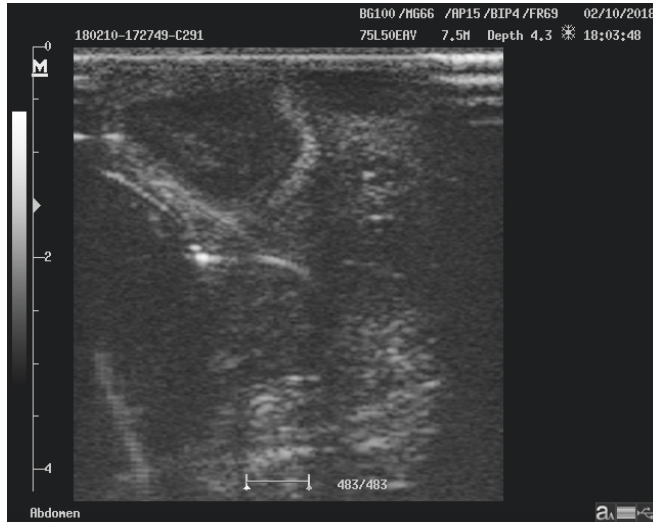

Figure 11. Ultrasonographic image of parovarian.

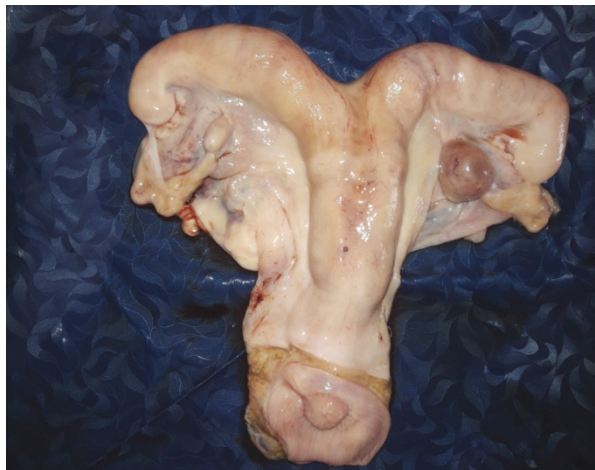

Figure 12. Unilateral ovarian hypoplasia.

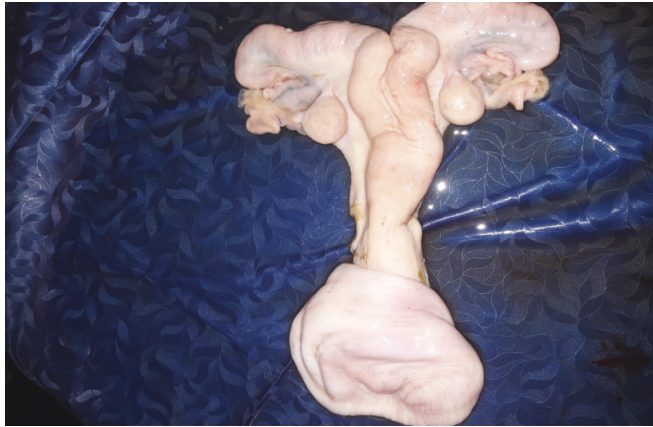

Figure 13. Bilateral ovarian hyperplasia.

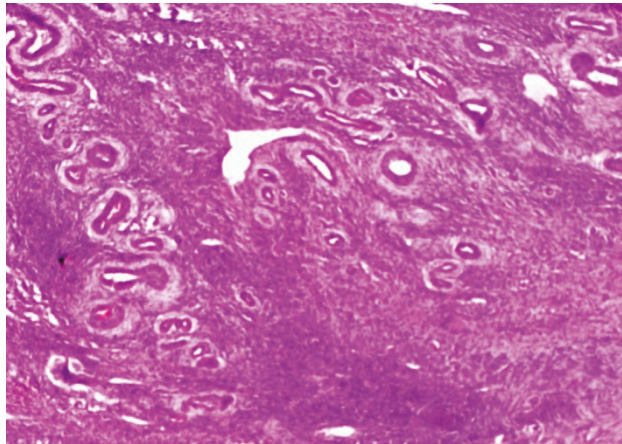


Figure 14. Sub active ovary, Tunica albuginia thick (H&E).

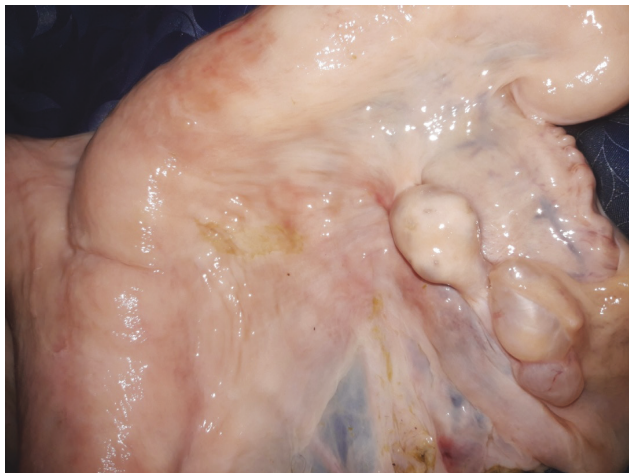


Figure 15. Ovarobursal adhesion.

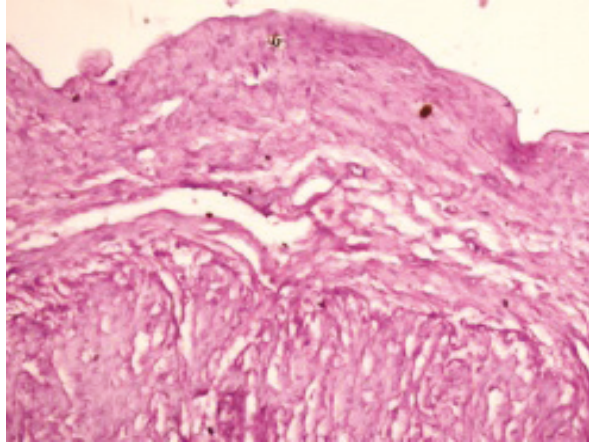


Figure 16. Ovariobursal adhesion (H&E).

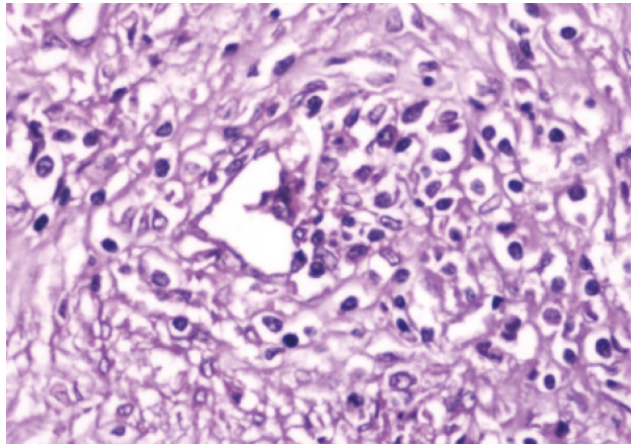


Figure 17. Oophoritis (H&E) thick (H&E).

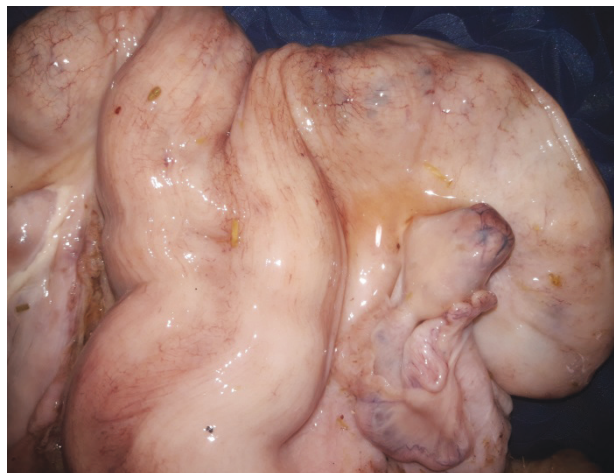

Figure 18. Ovarian haemorrhage.

trauma, ascending infection from uterus, rough manipulation of ovary, manual rupture of cyst or CL. Oophoritis is characterized by encapsulated shaggy ovarian surface and impaired ovulation due to adhesion. The high incidence of inflammatory conditions of the ovary could be due to ascending infection from the tubular genitalia as buffaloes were allowed to wallow in the contaminated water (Moogi, 1978; Kumar, 1981) and the same was found to be true in one case observed in this study wherein the inflammation was found extending from cervix to ovary. Summers *et al.* (1974) also suggested that the occurrence of mild interstitial oophoritis was independent and not ascending in origin and possibly resulted from infections or immunological processes.

The extensive fibrosis and adhesion with adjacent structures, atretic changes in follicles, and necrotic changes rendered the ovary functionless resulting in sterility (Figure 17), and the same was stated by Damodaran (1956); Dwivedi and Singh (1971). Ananda Raja (2003) also reported that severe adhesions with fibrosis might interfere with the ovulation and ovum transport into the fallopian tube.

The existence of oophoritis or perioophoritis with subacute nonsuppurative endosalpingitis in one case suggested possible ascending infection as observed by Damodaran (1956). Ovarian adhesions were produced by extensive inflammatory processes. Slight adhesions which could not be ascertained clinically obviously did not appear to interfere with the functional capacity of the infundibulum of the fallopian tube (Dwivedi and Singh, 1971) whereas adhesions were considered as significant contributors of sub-fertility by many workers (Bhattacharya *et al.*, 1954; Khan and Salam, 1967; Sharma *et al.*, 1967b; Kumar, 1981).

### Ovarian haemorrhage

Right ovaries were more frequently involved with ovarian haemorrhage (2 vs 1) with an overall incidence of 3.52% (total 3 cases) (Figure 18), characterized by enlargement (35 to 40 mm) and congestion with blood accumulation which was aspirated. However, others (Bhattacharya *et al.*, 1954; Damodaran, 1956; Khan and Salam, 1967; Sharma *et al.*, 1967b; Dwivedi and Singh, 1971; Rao and Rajya, 1976a; Ohashi *et al.*, 1984; Ghora, 1995) have reported a much lower incidence of below 1.43%. Focal intrafollicular haemorrhage might not affect the ovarian function and large follicular haematoma also did not show appreciable abnormality in the nearby ovarian stroma (Damodaran, 1956; Ghora, 1995). Whereas a little haemorrhage occurring in the luteal cavity was considered as a normal process in the vascularisation of CL (Damodaran, 1956). As Khan and Salam (1967) suggested, the haematoma of the ovary might be attributed to ovarian massage.

### REFERENCES

- Al-Fahadn T.A., A.F. Alwan and N.S. Ibraheem. 2004. Histological and morphological study of abnormal cases of female reproductive system in Iraqi buffaloes. *Iraqi Journal of Veterinary Sciences*, **18**: 109-115.
- Ali, A. and A.K. Abdel-Razek. 2002. Ultrasonography in detecting uterine pathology in cattle and sheep. In 14<sup>th</sup> Annual Congress in Cooperation with Egyptian Veterinary Nutrition Association, Giza, Egypt.
- Alwan, A.F., A.N. Abdul-Hameed and D.J. Khammas. 2001. A macroscopical study of

- abnormal genitalia of Iraqi buffaloes. *Iraqi J. Vet. Sci.*, **14**: 129-132.
- Amin, F.A.M. 2016. *An Abattoir Study of the Congenital Abnormalities of Ovaries and Uterine Tubes in Slaughtered Non-Pregnant Cows in Sulaimani Province*. College of Veterinary Medicine, University of Sulaimani, Sulaimani, Iraq.
- Ananda Raja, R. 2003. *Studies on pathology of reproductive system of she buffalo*. M.V.Sc. Thesis, Acharya N.G. Ranga Agricultural University, Rajendra Nagar, Hyderabad, India.
- Azawi, O.I., A.J. Ali and E.H. Lazim. 2008a. Pathological and anatomical abnormalities affecting buffalo cows reproductive tracts in Mosul. *Iraqi Journal of Veterinary Sciences*, **22**(2): 59-67. DOI: 10.33899/ijvs.2008.5715
- Azawi, O.I. and A.J. Ali. 2011. A study on the prevalence of pathological abnormalities of the uterus diagnosed at post mortem of buffaloes in Mosul. *Buffalo Bull.*, **34**(1): 51-62. Available on: [https://kukrdb.lib.ku.ac.th/journal/BuffaloBulletin/search\\_detail/result/286322](https://kukrdb.lib.ku.ac.th/journal/BuffaloBulletin/search_detail/result/286322)
- Bage, R., H. Gustafsson, M. Forsberg, B. Larsson and H. Rodriguez-Martinez. 1997. Suprabasal progesterone levels in repeat breeder heifers during the pro- and oestrous period. *Theriogenology*, **47**(1): 141.
- Bhattacharya, P., S.N. Luktuke, A.S.P. Rao and S.K. De. 1954. Incidence of infertility under various causal group in buffalo cows in India. *Curr. Sci. India*, **23**: 335-336.
- Bukhan. 1970. Incidence of various diseases and disorders of bovine ovary. *Journal of the Remount and Veterinary Corps*, **9**: 2-8.
- Butani, M.G., R. Kumar, A.J. Dhama, F.S. Kavani and A. Killedar. 2008. Incidence of major infertility problems in crossbred cows and buffaloes under field conditions. *Indian Journal of Field Veterinarians*, **4**(2): 1-4.
- Butani, M.G., A.J. Dhama, R. Kumar, N.D. Hirani, V.P. Ramani and K.P. Patel. 2009. Influence of hormonal and antibiotics therapy on fertility and trace minerals profile in repeat breeding buffaloes. *Indian Journal of Field Veterinarians*, **4**(3): 12-16.
- Chauhan, F.S. and M. Singh. 1979. Anestrus in buffaloes. *Indian Vet. J.*, **56**: 583-589.
- Damodaran, S. 1956. *Studies on genital pathology of the female buffalo (Bos bubalis)*. M.Sc. Thesis, University of Madras, Chennai, India.
- Des Cooteaux L., P.D. Carrier and J. Durocher. 2006. Ultrasonography of the reproductive system of the cow: basic principles, practical uses and economic aspects of this diagnostic tool in dairy production. *The 24<sup>th</sup> World Buiatrics Congress*, Nice, France. Available on: [http://real.mtak.hu/88070/1/AWETH201801022036\\_doi.pdf](http://real.mtak.hu/88070/1/AWETH201801022036_doi.pdf)
- DesCooteaux L., G. Gnemmi and J. Colloton. 2009. Ultrasonography of the bovine female genital tract. *Vet. Clin. N. Am. Food A.*, **25**(3): 733-752. DOI: 10.1016/j.cvfa.2009.07.009
- Dwivedi, J.N. and C.M. Singh. 1971. Studies on the pathology of female reproductive organs of Indian buffaloes. 1. Ovarian abnormalities. *Indian J. Anim. Health*, **41**: 10-27.
- Dwivedi, J.N. and C.M. Singh 1975. Studies on the folliculoids in ovaries of Indian buffaloes. *Indian. J. Anim. Sci.*, **45**: 15-20.
- El-Sawaf, S. and K. Schmidt. 1963. Morphological changes in normal and abnormal ovaries of buffaloes with special reference to their function. *Vet. Med. J.*, (Cairo), **8**: 249.
- Fissore, R.A., A.J. Edmondson, R.L. Pashecn and

- R.H. Bondurent. 1986. The use of. *Indian Vet. J.*, **44**(7): 572-575.
- Khan, M.Z. 1991. Prevalence of pathology of disease conditions of ovaries of *Nili-Ravi* buffaloes. *Buffalo J.*, **2**: 215-223.
- Khanna, A.K., N.C. Sharma and Kalicharan. 1995. Fallopian tube abnormalities in buffaloes. *Indian J. Anim. Sci.*, **65**: 282-284.
- Kimura, M., T. Nakao, M. Moriyoshi, and K. Kawata. 1987. Luteal phase deficiency as a possible cause of repeat breeding in dairy cows. *Brit. Vet. J.*, **143**(6): 560-566. DOI: 10.1016/0007-1935(87)90047-9
- Kodagali, S.B. and V.K. Kerur. 1968. Genital abnormalities in Jafri buffalo cows. *Gujarat Veterinary*, **2**: 29.
- Kumar, R., M. Butani, F. Kavani, A. Dhama, R. Shah, N. Sarvaiya and A. Killedar. 2008. Influence of hormonal and non-hormonal therapies on fertility and serum progesterone, metabolites and minerals profile in anoestrus crossbred cows. *Agricultural and Food Sciences, Medicine*. Available on: <https://www.semanticscholar.org/paper/Influence-of-Hormonal-and-Non-hormonal-Therapies-on-Kumar-Butani/26e4f292e3fab5c827175a73a5b1c0fe1d3d0354>
- Kumar, N. 1981. *Studies on the incidence and etiopathology of reproductive disorders female buffalo (Bubalus bubalis)*. Ph.D. Thesis, Punjab Agriculture University, Punjab, India.
- Kumar, R. 2008. *Studies on major infertility problems, their diagnosis and therapeutic management in crossbred cows under field conditions*. M.V.Sc. Thesis, Anand Agricultural University, Gujarat, India.
- Kumar, R., A.J. Dhama, M.G. Butani, F.S. Kavani, N.P. Sarvaiya and A. Killedar. 2010. Management of repeat breeding under field condition using hormonal and non hormonal drugs in cows. *Indian J. Anim. Reprod.*, **31**(1): 30-32.
- Kumar, R., M.G. Butani, A.J. Dhama, F.S. Kavani, R.G. Shah and A. Killedar. 2011. Management of anestrus and substructure cows using hormonal and non-hormonal drugs. *Indian J. Anim. Reprod.*, **32**(1): 24-27. DOI: 10.13140/RG.2.2.18786.79046
- Kumar, R., M.G. Butani, A.J. Dhama, F.S. Kavani and R.G. Shah. 2009. Effect of different therapies on fertility and serum progesterone, metabolites and minerals profile in repeat breeding crossbred cows. *Indian Journal of Field Veterinarians*, **5**(2): 1-8.
- Kunbhar, K.H., M.U. Samo, R. Rind, I. Kaka and D.A. Channa. 2003. Gross pathological studies on female reproductive organs of Thari cow (*Bos Indicus*). *Journal of Animal and Veterinary Advances*, **2**(2): 58-63.
- Luktuke, S.N., A.R. Bhattacharya and S.K. Singh. 1973. Studies on aberrations in functional activity of the ovaries in buffaloes. *Indian Vet. J.*, **50**(9): 875.
- Luktuke, S.N., L.N. Purbey and N.S. Parihar. 1979. Studies on the anestrus in adult buffalo heifers. *Indian Vet. J.*, **56**: 380.
- Mittal, D., U.K. Garg, G.P. Jatav, S. Shukla and R. Sharda. 2010. Prevalence of different pathological affections of ovaries in buffaloes (*Bubalus bubalis*) in Malwa region of Madhya Pradesh. *Buffalo Bull.*, **29**(1): 39-42. Available on: [https://kukrdb.lib.ku.ac.th/journal/BuffaloBulletin/search\\_detail/result/286257](https://kukrdb.lib.ku.ac.th/journal/BuffaloBulletin/search_detail/result/286257)
- Moogi, V.M. 1978. *Studies on the incidence and*

- pathology of female reproductive organs of buffaloes*. M.V.Sc. Thesis, University of Agricultural Sciences, Bangalore, India.
- Namboothiripad, T.R.B. and S.N. Luktuke. 1978. Studies on the gonads and hypophysis cerebri of anoestrous buffaloes (*Bos bubalis*). *Kerala Journal of Veterinary Science*, **9**: 293.
- Naoki, L. 2007. Follicular cyst in dairy cows. *Anim. Sci. J.*, **78**(1): 1-6. DOI: 10.1111/j.1740-0929.2006.00397.x
- Oshashi, O.M., V.R. Vale Filho, W.G. Vale and J.S.D.E. Sousa. 1984. Occurrence of genital lesions in buffalo cows slaughtered at the abattoir I. Anomalies of ovary and uterine tube. *Arq. Bras. Med. Vet. Zoo.*, **36**: 29-39.
- Pesantez, J.L., O. Ortiz and H.J. Ceron. 2016. Incidence of ovarian follicular cyst and their effect upon reproductive performance in dairy cows. *Arch. Med. Vet.*, **48**: 289-291.
- Pierson, R.A. and O.J. Ginther. 1984. Ultrasonography for detection of pregnancy and study of embryonic development in heifers. *Theriogenology*, **22**(2): 225. DOI: 10.1016/0093-691x(84)90435-7
- Pierson, R.A. and O.J. Ginther. 1988. Theriogenology ultrasonic imaging of the ovaries and uterus in cattle. *Theriogenology*, **29**(1): 21-37.
- Rajamahendran, R., D.J. Ambrose and B. Burton. 1994. Clinical and research applications of real time ultrasonography in bovine reproduction: A review. *Canadian Vet. J.*, **35**(9): 563-572.
- Ramamohanarao, A., P. Narasimharao, and A.S.P. Rao. 1965. Some observation on genital abnormalities of cattle. *Indian Vet. J.*, **42**(10): 751-754.
- Rao, P.R. and B.S. Rajya. 1976. Pathoanatomy of the female genital tract of buffaloes. *Indian J. Anim. Sci.*, **46**(3): 125-130.
- Reeves, J.J., N.W. Rantanen and M. Hauser. 1984. Transrectal real-time ultrasound scanning of the cow reproductive tract. *Theriogenology*, **21**(3): 485-494.
- Ribeiro, H.F.L., F.R.P. Mourao, F.J.C. Monteiro, Rolim, S.T. Filho and W.G. Vale. 2016. Diagnosis of investigative pathology in the genital tract of buffaloes raised extensively in the state of Amapa, Amazon, Brazil. *Rev. Bras. Med. Vet.*, **38**(4): 358-364. Available on: <https://bjvm.org.br/BJVM/article/view/46/9>
- Saini, J.S., G.S. Dhaliwal, S.P.S. Ghuman and A. Kumar. 2008. Reliability of ultrasonography for diagnosing genital tract abnormalities in buffaloes. *Indian. J. Anim. Reprod.*, **29**(1): 106-111.
- Sane, C.R., A.S. Kaikini, B.R. Deshpande, G.S. Koranne and V.G. Desai. 1964. Study of biometry of genitalia of the Murrah buffalo cows (*Bubalus bubalis*). *Indian. Vet. J.*, **41**: 653-663.
- Sevimli, A., E. Ozenc and D.B. Acar. 2012. Oviduct cyst observed together with a uterine serosal inclusion cyst in the Anatolian water buffalo case report. *Acta Vet Brno.*, **81**(3): 235-237. DOI: 10.2754/avb201281030235
- Shalash, M.R. 1958. Abnormalities of sexual organs in buffalo cows. *Vet. Rec.*, **70**: 1225-1226.
- Sharma, O.P., R.C. Sharma and B.K. Soni. 1967. Studies on some aspects of ovarian abnormalities as a cause of infertility in buffalo cows (*Bos bubalis*). *Indian Vet J.*, **44**(6): 504-508.
- Shokeir, A.A. 1958. Observations on disease conditions and malformations of



- reproductive organs of slaughtered buffaloes. *Vet. Med. J.*, **5**: 265.
- Singh, N., F.S. Chauhan and M. Singh. 1979. Post partum ovarian activity and fertility in buffaloes. *Indian J. Dairy. Sci.*, **32**: 134-139.
- Sreemannarayana, O. and A.V. Narsimha Rao. 1997. A comparative study of infertility in crossbred cows and buffaloes under village management. *Indian J. Anim. Reprod.*, **18**(1): 46-47.
- Sujata, S. 2000. Pathology of reproductive organs in buffaloes of north Karnataka region. *Indian. J. Vet. Pathol.*, **24**: 150.
- Summers, P.M., R.S.F. Campbell and D.P. Denett. 1974. Herd Studies on the genital pathology of infertile beef cows. *Aust. Vet. J.*, **50**(4): 150. DOI: 10.1111/j.1751-0813.1974.tb06881.x
- Tafti, A. and M.R. Darahshiri. 2000. Studies on the uterine abnormalities of slaughtered non-pregnant adult cows. *Indian. Vet. J.*, **77**(2): 1059-1062.
- Terzano, G.M. 2012. Ultrasonography and reproduction in buffalo. *Journal of Buffalo Science*, **1**: 163-173. DOI: 10.6000/1927-520X.2012.01.02.06
- Tomar, K.P.S., P. Singh, R. Singh and S. Singh. 2002. Seasonal variations in reproductive problems of buffaloes under field condition. *Indian J. Anim. Reprod.*, **23**(1): 18-20.
- Vale, W.G., J.S. Suza, O.M. Ohashi and H.F.L. Ribeiro. 1981. Anomalies of the tubular genital system of slaughtered buffaloes. *Pesqui. Vet. Beasil.*, **52**: 188-198.
- Youssef, F.A., A.A. Hegazy, M.R. Shalash and E.M. Ismail., 1991. Studies on histopathological reproductive changes in buffalo-cows. *Buffalo Journal*, **7**: 87-93.