

## MEDICINAL AND SURGICAL MANAGEMENT OF TAIL INFECTIONS IN BUFFALOES

**Manjunath Patil<sup>1,\*</sup>, Jajur Narayanashetty Sreedhara<sup>2</sup> and Desai Dilip Kumar<sup>3</sup>****ABSTRACT**

A study was conducted in 10 clinical cases of tail infections in buffaloes. Out of 10 buffaloes, 3 were Murrah, 2 each were Pandharpuri and Surti, 1 was Mehsana and 2 were non-descript-, respectively. The age of buffaloes ranged between 5 to 7 years old. Various tail infections were necrosis and gangrene of lower third of the tails and infected wound at tip of the tails, fracture at mid coccygeal region, varicose vein at upper third of the tail, traumatic injury at mid coccygeal region and maggot wound at the base of the tail near anus region. These cases were successfully managed either with conservative therapy or surgery.

**Keywords:** *Bubalus bubalis*, buffaloes, tail infections, medicine, surgery

**INTRODUCTION**

Buffalo is a more economic producer of milk than cow. The diseases that affect the productivity of the animal should be attended to prevent economic loss to the farmer. Buffalo with its tail; maintain its body hygiene by its wagging

movement either upwards or side wards. It also prevents the sitting of ectoparasites like flies, fleas, mosquitoes and ticks on its body (Alam *et al.*, 2010).

In spite of its normal anatomy and physiology, the tail is more prone to various infections like dermatitis, trauma, necrosis, gangrene, fracture, paralysis, luxation and disk spondylitis *etc.* (Nuss and Fiest, 2011). Necrosis of the tail may occur in any species but buffaloes seem to be more predisposed. The exact etiology remains unclear; however, multiple factors may operate to cause necrosis. The initial lesion is generally due to some form of trauma (Singh and Kumar, 2001). George *et al.* (1970) observed that tail gangrene in buffaloes was common and several possible causes were identified, including *Corynebacterium bovis*, deficiency of fatty acids and microfilaria. It has been reported that metabolic disturbances occur in the dermis and epidermis which have been indicated to be the predisposing cause for necrosis of the last vertebrae of the tail (Filipov *et al.*, 1986). The coccygeal vertebrae may get fractured or dislocated if the tail gets trapped between two fixed objects or due to trampling (Singh and Kumar, 2001). Alam *et al.* (2010) observed that water buffaloes had 39% tail injuries of which the

---

<sup>1</sup>Indian Council of Agricultural Research, Krishi Vigyan Kendra, Karnataka, India,

\*E-mail: manjunathpatil.2010@rediffmail.com

<sup>2</sup>Main Agri Agricultural Research Station, Karnataka, India

<sup>3</sup>Department of Veterinary Surgery and Radiology, Veterinary College, Karnataka, India

two major abnormalities were absent tail end (2%) and kinked tail (98%) in Bangladesh. So, greater attention to be paid with respect to management of tail infections in buffaloes. Hence, the present study reports various conservative and/ or surgical treatments for various infections of tail.

## MATERIALS AND METHODS

Ten buffaloes of different breeds weighing around 500 to 600 kg, aging 5 to 7 years old with various tail infections were presented to ICAR-Krishi Vigyan Kendra, Aland road, Kalaburagi, Karnataka, India. These animals were treated either by medicinal or surgical methods based on history of owners and clinical symptoms.

Tail amputation was carried out for irreparable injuries like necrosis and gangrene of lower third of the tail and infected wound at tip of the tail (Figure 1 and Figure 2), fracture at mid coccygeal region, varicose vein at upper third of the tail. Operation was done in standing position. The exact point of disarticulation was determined by palpation. Pre-operatively, the buffaloes were administered with amoxicillin sodium and cloxacillin sodium injection (10 mg/ kg body weight) and meloxicam injection (0.5 mg/kg body weight) intramuscularly. Design of study is given in Table 1.

Routine aseptic procedures were followed. Surgery was done with sedation of xylazine hydrochloride (0.1 mg/kg body weight intramuscularly) and posterior epidural anaesthesia by using 2% lignocaine hydrochloride. The 18 G hypodermic needle was introduced at an angle of 45° to the depth of about 0.5 to 1 inch to enter the vertebral canal. An amount of 6 ml of 2% lignocaine hydrochloride was administered slowly

to achieve caudal desensitization of the tail. After application of tourniquet at the base of the tail, a semicircular shaped incision was made on the skin to raise two triangular flaps of skin, the bases of which corresponded to the intervertebral space through which the disarticulation is to be effected. Cut through the intervertebral space (Figure 3).

Ligature of the two lateral and middle coccygeal arteries were made very easily with transfixation technique by using chromic catgut No. 2. Hemorrhage during the operation was controlled by a tourniquet which was released subsequently and the bleeding points if any were ligatured or torsioned with haemostatic forceps. The skin flaps were sutured by simple interrupted sutures using braided silk No. 2 (Figure 4). The excessive skin was trimmed for perfect apposition of the skin edges. Post-operatively, amoxicillin sodium and cloxacillin sodium injection (10 mg/ kg body weight) and meloxicam injection (0.5 mg/ kg body weight) intramuscularly for 5 days were administered. Daily surgical wound was dressed and antiseptic cream applied. The wound was healed (Figure 5) on 15<sup>th</sup> day after surgery and skin sutures were removed on 15<sup>th</sup> post-operative day.

## RESULTS AND DISCUSSION

Medicinal and surgical treatments of each case were discussed under the following sub headings.

### **Necrosis and gangrene of lower third of the tails and infected wound at tip of the tails**

Three Murrah buffaloes had infections of necrosis and gangrene of lower third of the tails and infected wound at the tip of the tails. Surgery was done for these cases by amputating the tail in

between 5<sup>th</sup> and 6<sup>th</sup> coccygeal vertebra. Drolia *et al.* (1991) administered antibiotics and performed amputation of the tail as a therapeutic or preventive measure for treatment of tail-tip necrosis in Ontario beef feed lot cattle. Dhillon and Singh (2003) stated that amputation has been the only effective treatment for this infection. Ural *et al.* (2007) treated by amputation, administration of antibiotics and topical antibacterial applications. Akioye *et al.* (2010); Nuss and Fiest (2011) suggested a cranial amputation of the affected area. They opined, the injuries near the end of the tail often resulted in dry gangrene and suggested that the tail should be dealt with amputations long before it got to the point of drying and becoming brittle.

Diseases of the tail did not respond to the routine medical management and demand amputation of the tail. Tail amputation in cattle was a very controversial subject because in some countries, it was carried out prophylactically for management reasons without any medical indication.

### **Fracture at mid coccygeal region**

Two Pandharpuri buffaloes had fracture at mid coccygeal region. One buffalo had fracture due to trampling of stone. Another buffalo had fractured by the owner himself by twisting the tail to make the animal stand or move. Amputation at upper third of tail was followed for these two cases. Similar procedure was followed by Satyanarayana *et al.* (2014) in buffaloes which had complete fracture at middle or upper third or at the tip, amputation was carried out.

### **Varicose vein at upper third of tail**

Two Surti buffaloes had varicosed vein tail with alopecia, advanced stage of necrosis and gangrene. Vein varicosis may either be congenital

or acquired in origin due to repeated vascular trauma or proximal occlusion or insufficiency of valves or sequel to arteriovenous shunt. Due to poor venous drainage, the cutaneous vessels get engorged with blood and become dilated, tortuous, elongated and lose their elasticity to form varicose veins (O'Connor, 2001; Kulkarni *et al.*, 2005). This may result in diminished perfusion and peripheral local ischemia (Ramakrishna, 2001).

In the present study, the two varicose vein tail cases with advance stage of necrosis and gangrene were amputated in between 2<sup>nd</sup> and 3<sup>rd</sup> inter-coccygeal vertebra. Similar procedure was adopted by Jena and Sahoo (2014) they reported that to prevent further progression of necrosis and gangrene due to varicosity, amputation of affected portion of the tail was practiced under caudal epidural anaesthesia in a 9 year old Murrah cross bred buffalo.

In contrary, Satyanarayana *et al.* (2014) reported that injection vitamin-A (450 IU/kg body weight) on alternate days for 5 injections intramuscularly and Polidocanol injection (Asclera 6 ml/buffalo) directly into the varicose vein for three consecutive weeks were administered. Kulkarni *et al.* (2005) reported that treatment of varicose vein by compression with bandage, firing, and ligation of vein above and below the swelling. These two cases were treated in initial stages of varicosity of tail in buffaloes and yet necrosis and gangrene was not set up.

### **Traumatic injury at mid coccygeal region**

In the present study, a Mehsana buffalo had traumatic injury at mid coccygeal region. This case was treated conservatively by parenteral administration of strepto-penicillin (5.0 g/ buffalo) and anti-inflammatory meloxicam injection (0.5 mg/kg body weight) intramuscularly for 5



Figure 1. Murrah buffalo with necrosis, gangrene at lower third of the tail and infected wound at tip of the tail.

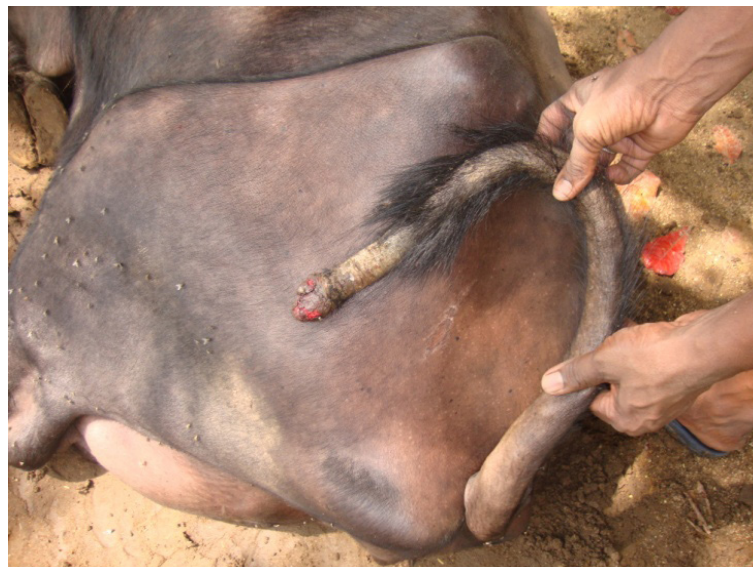

Figure 2. Arrow showing necrosis, gangrene at lower third of the tail and infected wound at tip of the tail.

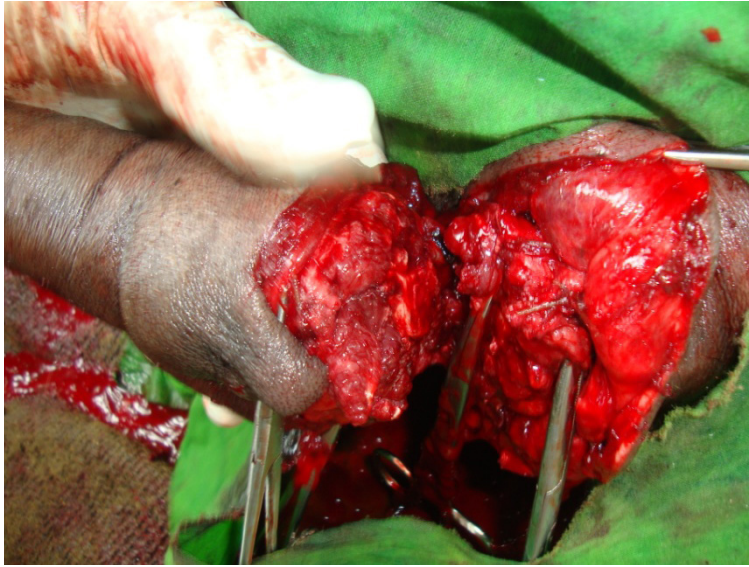

Figure 3. Intervertebral space disarticulation by transaction.

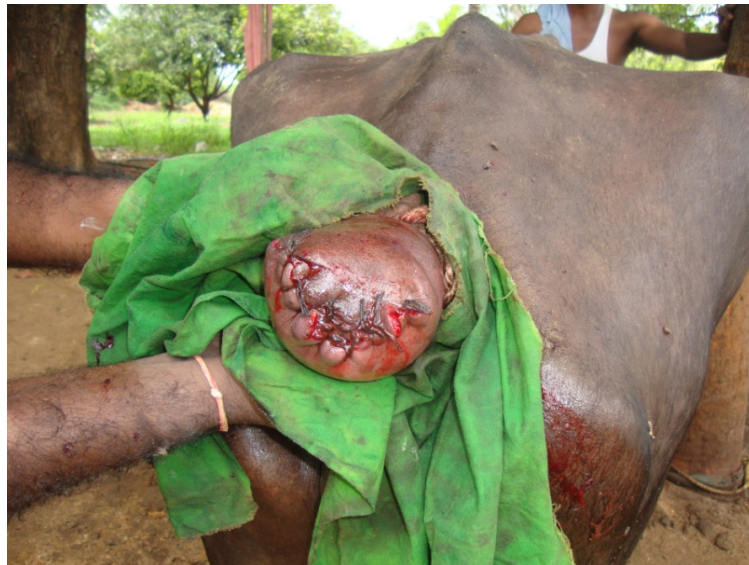

Figure 4. Skin is sutured by simple interrupted suture with silk no.2.

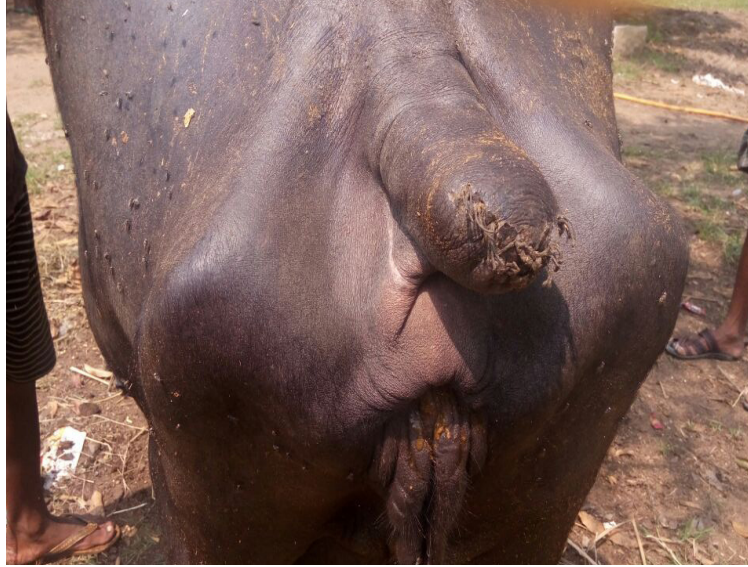


Figure 5. Wound healing on 15<sup>th</sup> day.

Table 1. Design of research work (N=10).

Breed	Infections	Treatment followed	Remarks
Murrah (N=3)	Necrosis and gangrene of lower third of the tails and infected wound at the tip of the tails	Amputation at upper third of the tails	Animals showed uneventful recovery without any lesions
P a n d h a r p u r i (N=2)	Fracture at mid coccygeal region	Amputation at upper third of the tails	Animals showed uneventful recovery without any lesions
Surti (N=2)	Varicose vein at upper third of the tails	Amputation of the tails	Animals showed uneventful recovery without any lesions
Mehsana (N=1)	Traumatic injury at mid coccygeal region	Medicinal treatment	Animal showed uneventful recovery without any lesions
N o n - d e s c r i p t (N=2)	Maggot wound at the base of tail near anus region	Medicinal treatment	Animals showed uneventful recovery without any lesions

days and applying cotton dipped tincture iodine solution on traumatic wound and topical gamma benzene hexachloride and proflavine ointment. Satyanarayana *et al.* (2014) dressed with povidone-iodine ointment and topical loraxene ointment for trauma on the tail of buffaloes and these cases were recovered without any complications. Kumar (2016) reported a case of degnala disease in a buffalo calf and treated with long acting oxytetracycline (20 mg/kg body weight) and same dosage was repeated after 72 h, isofluperidone (5 ml/buffalo calf) and B-complex with liver extract (5 ml/buffalo calf) intramuscularly for five days, along with this oral feeding of penta salts of copper, iron, cobalt, zinc and manganese (30 g/day) was given till recovery.

#### **Maggot wound at the base of tail near anus region**

Two non-descript buffaloes had traumatic myiasis at the base of tail near anus region due to faulty management of owner and heavy house fly population in and around buffalo shed. Conservative treatment was followed for these two cases. These cases were dressed by irrigating with 1: 5000 potassium permanganate solutions. Maggots that were superficial were removed with a forceps and gauze dipped in turpentine oil was allowed to remain in wound for about 24 h. The drug should be dropped deep to come in contact with the maggots. The gauze was removed next day and by that time most of the maggots might have been killed. Dead maggots were removed using forceps. These cases were administered parenterally with strepto-pencillin (5.0 g/buffalo) and meloxicam injection (0.5 mg/kg body weight) for 5 days. Topical application of gamma benzene hexachloride and proflavine ointment on maggot wound which acts as fly-repellent and antiseptic. Similar treatment procedure was followed for

cutaneous myiasis by *Chrysomya bezziana* in a traumatic wound at the base of tail in a five years old buffalo (Katoch *et al.*, 2013).

In conclusion, ten clinical cases of buffaloes with tail infections were managed successfully either with medicinal or surgical treatment. If the cases of tail infections are presented in earlier stage, conservative treatment can be followed by avoiding amputation procedure, their by saving the tail of animal.

### **REFERENCES**

- Akioye, O., Omobowale, Olaifa and Abiola. 2010. Tail Docking in an African Lion (*Panthera Leo*). *Isr. J. Vet. Med.*, **65**(2): 75-76.
- Alam, M.R., N.G. Gregory, M.S. Uddin, M.A. Jabbar, S. Chowdhury and N.C. Debnath. 2010. Frequency of nose and tail injuries in cattle and water buffalo at livestock markets in Bangladesh. *Animal Welfare*, **19**: 295-300.
- Dhillon, K. and J. Singh. 2003. Treatment of gangrene of tail in buffaloes. *Punjab Veterinary Journal*, **3**: 19-20.
- Droliia, H., U.A. Luesher, A.H. Meek and B.P. Wilcock. 1991. Tail-Tip necrosis in Ontario beef feed lot cattle. *Canadian Vet. J.*, **32**(1): 23-29.
- Filipov, Z.H., N. Bodurov, K. Binev and I. Borisov. 1986. Necrosis of tail in buffaloes. *Veterinarno Meditsinski Nauki*, **23**: 66-71.
- George, P.O., J.V. Chauran and N.M. Abyas. 1970. Necrosis of tail in bovine animals. *Vet. Rec.*, **87**: 231-233.
- Jena, B. and A. Sahoo. 2014. Amputation of tail with varicose veins in a buffalo - A case report. *International Journal of Livestock*

*Research*, **4**(9): 58-60.

- Katoch, R., R. Godara, A. Yadav, S. Sharma and I. Ahmad. 2013. Occurrence of *Chrysomya bezziana* in a buffalo in Jammu. *Journal of Parasitic Diseases*, **38**(4): 420-422.
- Kulkarni, M.D., A.S. Kadam, A.V. Khanvilkar and O.N. Ladukar. 2005. Vein varicosis in a Pandharpuri buffalo - A case report. *Buffalo Bull.*, **24**(2): 24.
- Kumar, M. 2016. Therapeutic management of Degnala disease in a buffalo calf: A case report. *International Journal of Agricultural Sciences and Veterinary Medicine*, **4**(1): 6-7.
- Nuss, L.K. and M. Fiest. 2011. Tail amputation for treatment of osteomyelitis of the first and second coccygeal vertebrae in a cow. *Tierarztl. Prax.*, **39** (4): 176-178.
- O'Connor, J.J. 2001. *Dollar's Veterinary Surgery*, 4<sup>th</sup> ed. CBS Publishers, New Delhi, India. p. 94-95.
- Ramakrishna, O. 2001. Cardiovascular system, p. 259. In Tyagi, R.P.S. and J. Singh (eds.) *Ruminant Surgery*, 1<sup>st</sup> ed. CBS Publishers, New Delhi, India.
- Satyanarayana, G., M. Sreenu, V.D. Prasad and G.V. Naidu. 2014. Management of tail affections in buffaloes. *International Journal of Agricultural Sciences and Veterinary Medicine*, **2**(4): 27-33.
- Singh, J. and A. Kumar. 2001. The integumentary system, p. 147. In Tyagi, R.P.S. and J. Singh (eds.) *Ruminant Surgery*, 1<sup>st</sup> ed. CBS Publishers, New Delhi, India.
- Ural, K., D. Alic, M. C.Karakurum, M.S. Aktas, A.E. Hydatedeoglu and C.C. Cingri. 2007. Tail tip necrosis in beef and dairy cattle: A report of seven cases in Ankara Kafkas. *Universitesi Veteriner Fakultesi Dergisi*, **13**(2): 203-207.