

RECTAL STRICTURE DUE TO CIRCUMFERENTIAL FIBROMA IN BUFFALOES

Vandana Sangwan^{1,*}, Ashwani Kumar¹ and Nitin Dev Singh²**ABSTRACT**

The present clinical study describes successful surgical management of a rectal stricture due to circumferential fibroma (fibrous ring) in two recently calved adult buffaloes. Both buffaloes had a chronic history of straining while defecation with no rectal prolapse. At presentation, these buffaloes were passing scanty and pasty feces. Per rectal examination revealed rectal stricture due to demarkable circumferential fibrous ring which was later histopathologically diagnosed as fibroma in the sub mucosa of the rectum. Surgical resection of the fibrous ring was done under caudal epidural anesthesia. Both buffaloes recovered uneventfully and no recurrence of this condition was observed on long term follow up of 4 years and six months, respectively.

Keywords: *Bubalus bubalis*, buffalo, bovine, fecal obstruction, fibrous ring, fibroma, straining, surgery

INTRODUCTION

Stricture is a narrowing of the lumen due to cicatricial tissue. Injury to the rectum due

to foreign bodies or trauma, neoplasia or fat necrosis impinging on or within the lumen or from defects associated with rectal and vaginal strictures may result in rectal strictures in cattle (Kahn and Line, 2010). Various tumors such as scirrhus adenocarcinoma (Suzuki and Ohshima, 1993), fibroma (Bose *et al.*, 1981) and poorly differentiated carcinoid (Michishita *et al.*, 2007) of the rectum have been reported in cattle. The recto-vaginal stricture in cattle may also be congenital (Radostits *et al.*, 2007). Acquired rectal stricture in the feeder pigs of 2 to 3 months has also been reported due to *Salmonella typhimurium*; though, it has been suggested that there was an inherited component in the etiology. The rectal stricture in pigs has been reported to be 2 to 5 cm anterior to the anus and can be felt with digital palpation (Jackson and Cockcroft, 2002; Radostits *et al.*, 2007).

The treatment of rectal stricture in small animals is usually balloon dilation combined with intra lesional injections of long acting corticosteroids such as triamcinolone. But in large animals it usually includes resection of the strictured area using rectal pull through technique (Kahn and Line, 2010). Occurrence and surgical management of caudal rectal tumors have also been described in buffaloes (Mosbah and Naggar, 2012) but associated rectal stricture which could have led

¹Department of Veterinary Surgery and Radiology, College of Veterinary Science, Guru Angad Dev Veterinary and Animal Sciences University, Punjab, India, *E-mail: drvandanasangwan@rediffmail.com

²Department of Veterinary Pathology, College of Veterinary Science, Guru Angad Dev Veterinary and Animal Sciences University, Punjab, India,

to difficult defecation has not been mentioned. The present case report describes two cases of buffalo having rectal strictures due to fibrous ring, later diagnosed to be a fibroma, which were successfully surgically treated by resection of the stricture area.

CASE HISTORY AND PRESENTATION

Two recently calved, non-gravid buffaloes were presented to the department of Veterinary Surgery and Radiology at different times with the chronic history of straining while defecation of feces. The detailed signalment, history and clinical presentation of these buffaloes has been given in Table 1.

Per rectal examination revealed rectal lumen stricture at a depth of about 10 cm from the anus in both the cases. The stricture could be pulled out of anus using finger (Figure 2). Only one finger opening in buffalo 2 and three fingers in buffalo 1 was present in the stricture region. A circumferential fibrous ring in the rectal mucosa was felt causing the stricture. Considering the findings, resection of the stricture ring was planned under caudal epidural anesthesia.

TREATMENT AND DISCUSSION

The surgical intervention was done under caudal epidural anesthesia by injecting 5 ml of inj. lignocaine Hcl 2% into the sacro-coccygeal space. The onset of anesthesia was observed within 10 minutes. The surgical site was cleaned and prepared aseptically. By pulling the stricture out of the anus with the help of finger, two stay sutures were applied using silk No. 2 at 3 and 9 o' clock position of the stricture (Figure 3). The sutures

were grasped with artery forceps and pulled, so that the stricture site could be visualized and made stable during surgical maneuver. A circumferential incision was made on the rectal mucosa over the fibrous ring. The fibrous tissue causing stricture was dissected out (Figure 4). Four horizontal mattress sutures were applied at four quadrants to oppose the mucosal incision using catgut no. 1 in buffalo I; however, no sutures were applied in buffalo II. After surgery, the rectal lumen was large enough (Figure 5) to pass full hand. The resected tissue was subjected to histopathological examination. Post operatively inj. Ampicillin-Cloxacillin 10 mg/kg and inj Gentamicin 2 mg/kg, twice daily, intramuscularly, were administered for 5 and 3 days, respectively along with inj. Meloxicam 0.2 mg/kg, once daily, for 3 days. Daily application of soframycin cream and lignocaine jelly was advised at the surgery site inside the rectum for 5 to 7 days. It was also advised to pass full hand into the rectum, 2 to 3 times daily for 10 days to act as a dilator.

Histopathologically, well circumscribed nodules of dense fibrous tissue with occasional spindle cells having scant cytoplasm and elongate nuclei with evenly distributed fine chromatin were seen on H & E stain. The collagenous fibers were repetitive and were arranged in interwoven fascicles. On the basis of these findings, the condition was diagnosed as fibroma (Figure 6). Telephonic follow up at regular intervals up to 4 years in buffalo I and 6 months in buffalo II revealed these to be healthy, with good reproductive status and were passing normal feces without straining.

Rectal stricture has been reported as a congenital condition in cattle along with vaginal involvement (Radostits *et al.*, 2007) though other reasons like foreign body, neoplasia or fat necrosis in the rectum have also been reported to be the causes of rectal stricture in cattle (Kahn and Line,

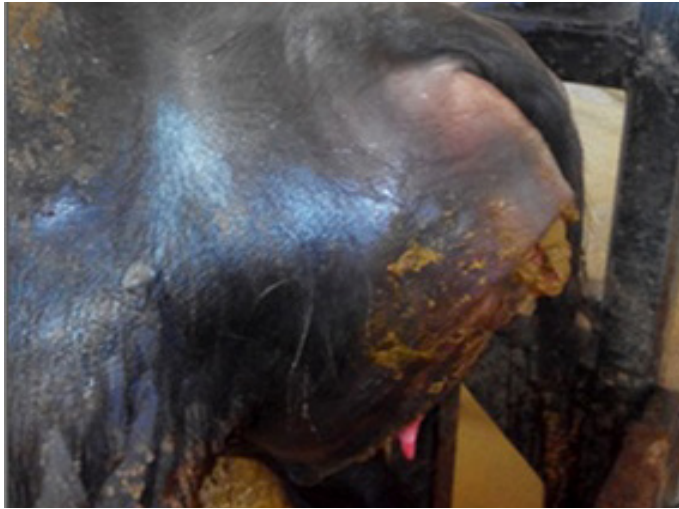

Figure 1. Photograph showing frequent and excessive straining with bulging of almost 15 cm of anal area while defecation of feces.

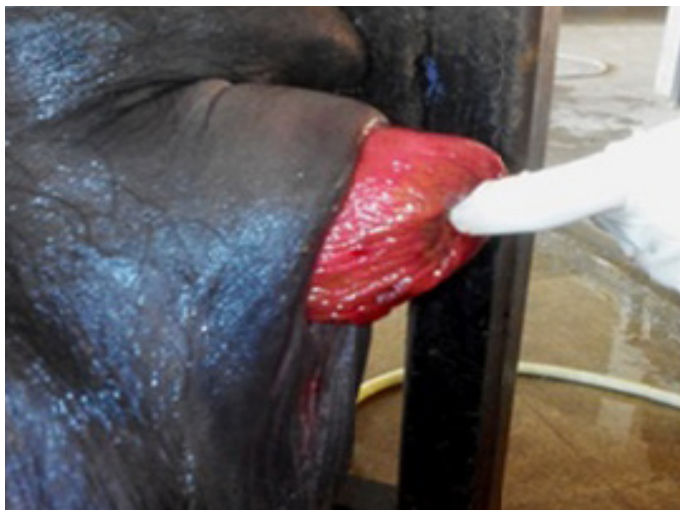

Figure 2. Photograph showing site of rectal stricture.

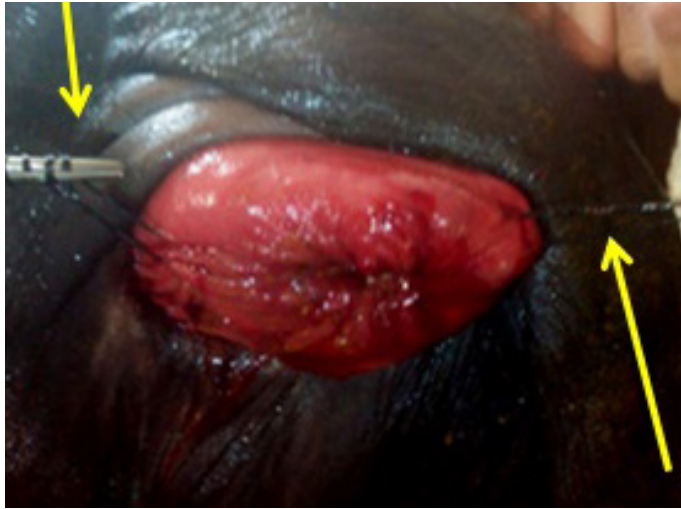

Figure 3. Photograph showing rectal stricture with stay sutures at 3 and 9 '0 clock position (yellow arrow).

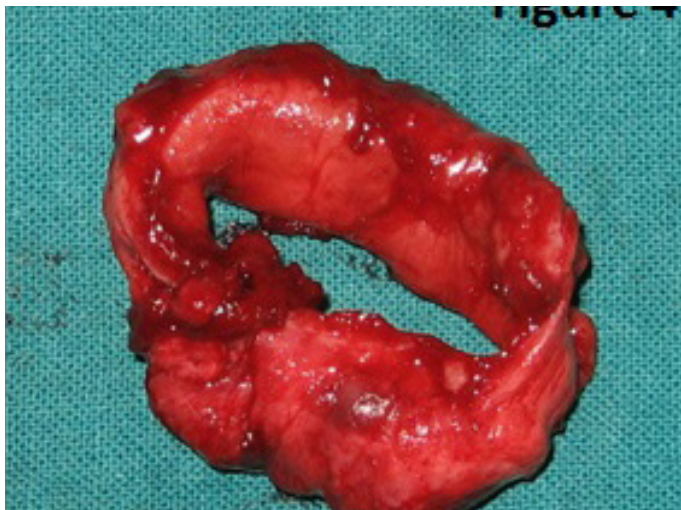


Figure 4. Photograph showing resected fibrous ring.

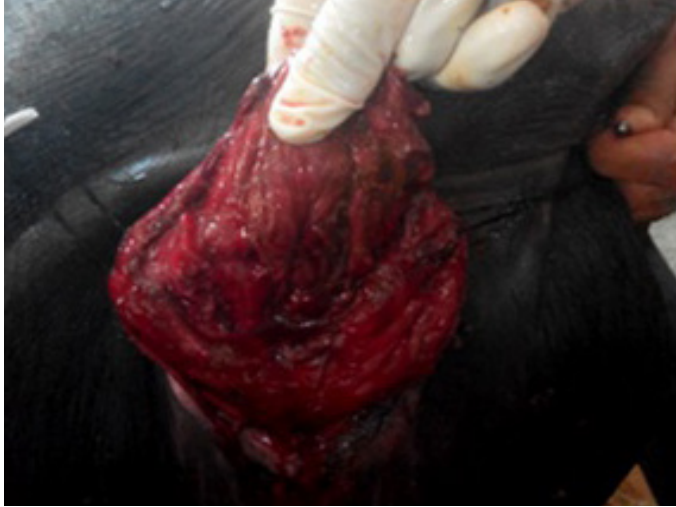

Figure 5. Photograph showing widening of rectal opening after surgery.

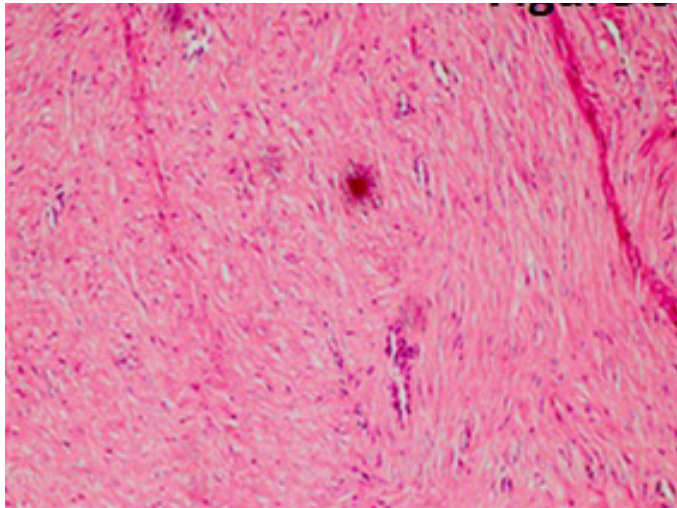


Figure 6. Photograph showing H and E stain of histological sample in 10x showing typical features of fibroma.

2010). The pigs suffering from rectal stricture have been reported with clinical signs of progressive abdominal distension, inappetence, emaciation, dehydration and watery to pasty feces (Jackson and Cockcroft, 2002; Radostits *et al.*, 2007). However, the buffaloes in the present study had no apparent abdominal distension, though straining was persistent. Para rectal abscess (Sangwan *et al.*, 2008) or cyst (Sangwan *et al.*, 2011) in bullock and buffalo, respectively are also been reported as the cause of frequent straining while defecation of feces. Per rectal examination/ digital palpation along with certain biochemical tests and needle centesis are sometimes required to differentiate these conditions (Jackson and Cockcroft, 2002; Radostits *et al.*, 2007; Sangwan *et al.*, 2008; Sangwan *et al.*, 2011). Caudal epidural anesthesia has been reported to be sufficient for perianal region (Sangwan *et al.*, 2008; Sangwan *et al.*, 2011). In pigs the stricture can be felt digitally at 2 to 5 cm anterior to the anus (Radostits *et al.*, 2007 and Jackson and Cockcroft, 2002), while in the present cases, it was felt almost 10 cm anterior to the anus. Incision at the dorsal and lateral aspect of the

stricture or complete resection of the stricture area using pull through technique has been suggested in large animals (Kahn and Line, 2010) but no such report in buffaloes could be traceable. In the present report complete removal of the fibrous ring causing stricture was found to successful in both the buffaloes on long term follow up.

REFERENCES

- Bose, A.S., O. Ramakrishna and N.T. Krishnamurthy. 1981. Surgical repair of a rectal fibroma in a bull. *Vet. Med. Sm. Anim. Clin.*, **76**(9): 1349-1350.
- Jackson, P.G.G. and P.D. Cockcroft. 2002. Clinical Examination of pig. *Clinical Examination of Farm Animals*, 1st ed. Blackwell Publishing Company, UK.
- Kahn, C.M. and S. Line. 2010. *The Merck Veterinary Manual*. Published by Merck and Co. Inc. New Jersey, USA.
- Michishita, M., K. Takahashi, H. Moriya, S. Nakamura, H. Koyama and T. Sako. 2007.

Table 1. Clinical signs and signalment of the buffaloes with rectal stricture.

Parameter	Buffalo 1	Buffalo 2
Age (year)	6	5
Weight (Kg)	550	350
Physiological status	calved 6 weeks back	calved 8 weeks back
History of dystocia	None	None
Chronicity of illness	3 weeks	More than 4 week old
Straining while defecation	Moderate straining with less bulging of anus	Severe straining with bulging of almost 15 cm of anal area (Figure1)
Feces	Small quantity of pasty flat feces	Very small quantity of pasty feces were passed
Feed and water status	Normal	Partial anorexia

- Poorly differentiated rectal carcinoid in a cow. *Vet. Pathol.*, **44**(3): 414-417.
- Mosbah, E. and A.El. Naggar. 2012. Surgical management of caudal rectal tumors in buffaloes. *Res. J. Dairy Sci.*, **6**(1): 1-4.
- Radostits, O.M., C.C. Gay, K.W. Hinchcliff and P.D. Constable. 2007. *Veterinary Medicine A textbook of the Diseases of Cattle, Horses, Sheep, Pigs and Goats*, 10th ed. Saunders Philadelphia, USA. p. 279-280.
- Sangwan, V., A. Kumar., N.S. Saini and J. Mohindroo. 2011. Perirectal cyst causing rectal obstruction in a buffalo heifer. *Buffalo Bull.*, **30**(4): 176-179.
- Sangwan, V., J. Mohindroo, N.S. Saini, A. Kumar and M. Raghunath. 2008. Surgical management of peri-rectal abscess in racing haryana bullock. *Indian J. Vet. Surg.*, **29**(1): 59-60.
- Suzuki, T. and K. Ohshima. 1993. Scirrhus adenocarcinoma of the rectum in a cow. *J. Vet. Med. Sci.*, **55**(6): 1063-1065.