

PER-VAGINAL DELIVERY OF HYDROCEPHALIC FETUS ASSOCIATED WITH MUSCULO-SKELETAL DEFECTS IN A MURRAH BUFFALO

Rishipal Yadav, Gitesh Saini, Pradeep and Ravi Dutt*

ABSTRACT

The present communication reports a rare case of dystocia due to intra-cranial hydrocephalic fetus associated with ankylosis of limbs in a pleuriparous Murrah buffalo and per-vaginal delivery by forced extraction using obstetrical maneuvers.

Keywords: *Bubalus bubalis*, buffaloes, ankylosis, dystocia, hydrocephalic fetus, Murrah buffalo, per-vaginal delivery

INTRODUCTION

Dropsical conditions of the fetus often result into dystocia and hydrocephalus refers to accumulation of excessive fluid into the cranial cavity. Excessive swelling of cranial cavity during fetal development is the result of obstruction in free passage of cerebrospinal fluid into the arachnoid space (Salunke *et al.*, 2001) as a result of disturbance in normal flow of cerebral spinal fluid (CSF) and its reabsorption. Hydrocephalus is of two types: One is internal hydrocephalus which occurs due to collection of fluid in the cerebral ventricles, and other is external hydrocephalus which is due to collection of fluid in the sub-arachnoid spaces

(Noakes *et al.*, 2019). Congenital hydrocephalus has been described in various animal species including cattle (Sharda and Ingole, 2002), buffalo (Bugalia *et al.*, 1990), mare (Sharma, 1996) and camel (Abubakr *et al.*, 1998). An autosomal recessive gene has been reported to be linked with hydrocephalus condition (Roberts, 1986), which may get exacerbated when coexisting with hypovitaminosis (Jubb and Kennedy, 1970) or causative factors may be genetic/environmental (Szabo, 1989). This report describes a case of dystocia in Murrah buffalo caused by hydrocephalic foetus associated with musculoskeletal defects i.e. ankylosis of limbs and delivered per-vaginally with traction after converting into posterior presentation.

CASE HISTORY AND OBSERVATIONS

A seven-year-old Murrah buffalo in its third parity at full term pregnancy was brought to Veterinary Clinical Complex, LUVAS Hisar with the history of active labour for last 8 h. History revealed that both the water bags had already ruptured and traction was applied at head by applying loop of rope around neck by field veterinarian. Animal was depressed, exhausted and vulvar lips were inflamed and edematous due

to excessive traction. Per-vaginal examination revealed fully dilated cervix and both forelimbs of dead fetus extended in birth canal, and hind limbs extended in the passage beneath the fetal body i.e. dog sitting posture.

TREATMENT AND DISCUSSION

After washing the perineum with diluted potassium permanganate solution (1:1000), epidural anaesthesia was achieved using 5 ml (inj. 2% Lignocaine hydrochloride) and 2 liters of liquid paraffin was introduced in birth canal. Both the forelimbs were pushed deep into the uterus. Both hind limbs were brought in vaginal region and after application of snares hand guided traction was applied and fetus was delivered.

There was marked enlargement of cranium associated with brachygnathism, ankylosis of limbs and spinal curvature (Figure 1A). Radiography and post-mortem examination confirmed that it a case of intracranial hydrocephalic fetus (Figure 1B and 1C). Joints of limbs mainly of left hind and left forelimb were ankylosed (Figure 2A and 2B). Gross examination of internal organs revealed left kidney as cystic (Figure 3), congestion in lungs liver and heart (Figure 4, 5 and 6). The brain was rudimentary fibrous band like (Figure 7). S-shaped curvature of lumbar vertebrates was also recorded (Figure 8). The case was diagnosed as dystocia due to hydrocephalic fetus associated with ankylosis and brachygnathism.

Dam was administered intravenous fluid (Normal saline solution 3 liters IV for 3 days) and supportive therapy along with antibiotics (Cefoperazone plus sulbactam 4.5 g and metronidazole 5 g for 5 days) and NSAID (Flunixin meglumine 1.1 mg/kg for 5 days). Cloprostenol

500 microgram IM and oxytocin 50 I.U. in 500 ml normal saline solution IV were also administered immediately after delivery of dead fetus. The dam recovered uneventfully.

The delivered fetus was intra cranial hydrocephalic as described by (Purohit *et al.*, 2012) associated with ankylosed left hind and fore limbs, S-shaped curvature of spine and brachygnathism. Hydrocephalus with concurrent brachygnathism is seen in bovine viral diarrhoea (BVD) virus infected calf at mid-gestation (Noakes *et al.*, 2019). Upasana *et al.* (2012) described the relationship of blue tongue virus with hydrocephaly. Hydrocephalus may occur alone or associated with other deformities. The cause of dystocia is usually enlarged size of head which can be relieved by incising soft portion of head, forced traction and mutation and at the last caesarean hysterectomy. It is rare in buffaloes (Kumaresan *et al.*, 2003). In the present case enough uterine space was available and fetus was converted into posterior presentation, as it is quite easy to relieve dystocia in posterior presentation as compared to anterior presentation. After puncturing the fetal head with trocar and cannula, per vaginal delivery was achieved successfully by Tripathi *et al.* (2014) but in the current case the fetus was comparatively smaller, so, per-vaginal delivery was performed with ease.

REFERENCES

- Abubakr, M.I., A.A. Ahmed, N.M. Nayel and M.E. Fadlalla. 1988. Hydrocephalus in a new born male camel calf. *J. Camel Pract. Res.*, 5(2): 309.
- Bugalia, N.S., S. Chander, R.K. Chandolia, S.K. Verma, P. Singh and O.K. Sharma. 1990.



Figure 1A. Fetus with enlarged cranium and brachygnathism.

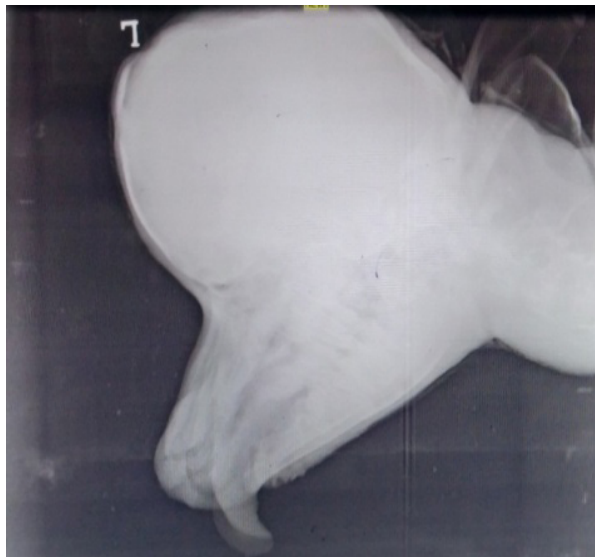


Figure 1B. Radiographic image of enlarged cranium.

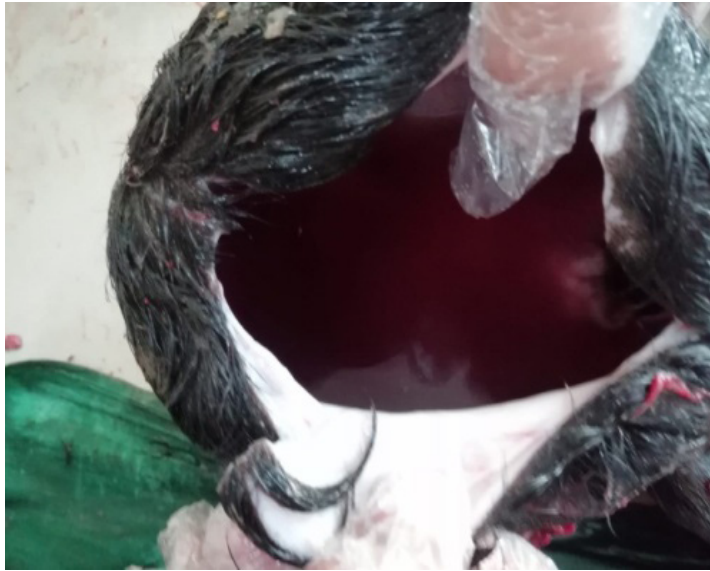

Figure 1C. Fluid filled cranial cavity of fetus.

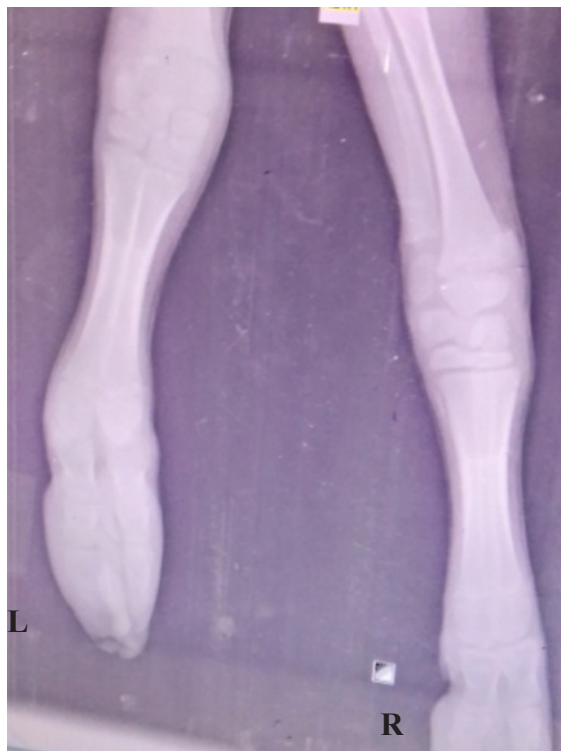


Figure 2A. Radiographic image of forelimbs showing ankylosis in left limb.

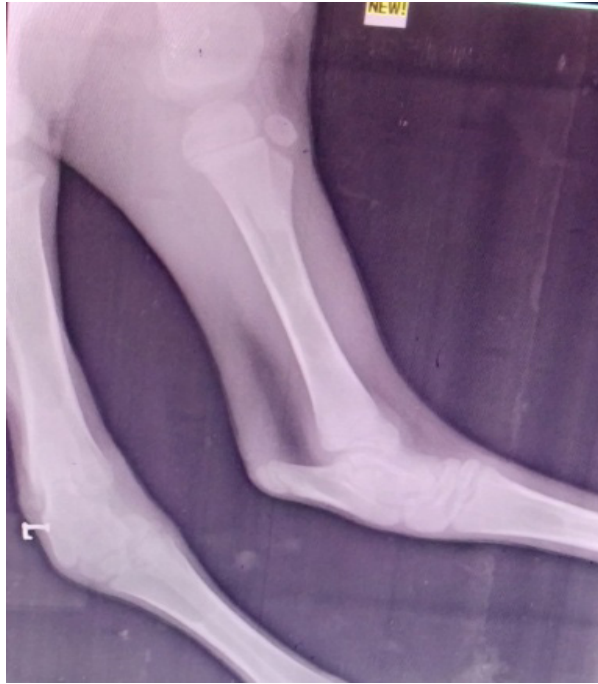

Figure 2B. Radiographic image of hindlimbs showing ankylosis in left hind limb.

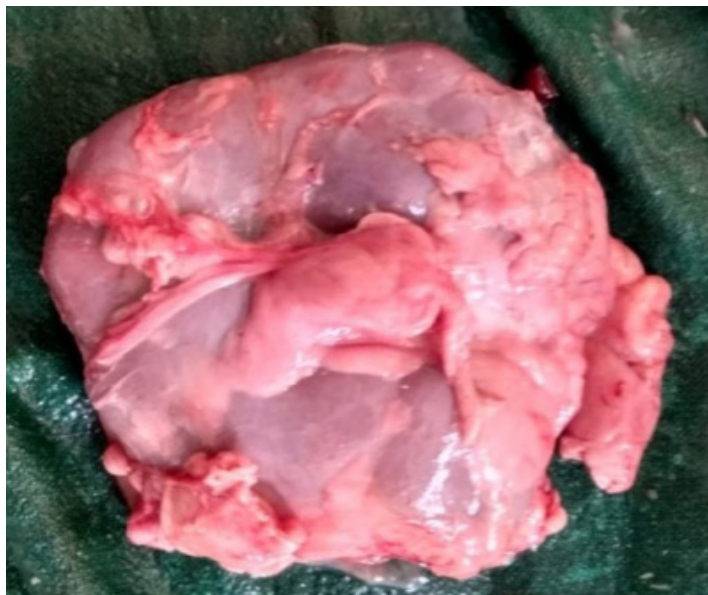

Figure 3. Cystic left kidney.

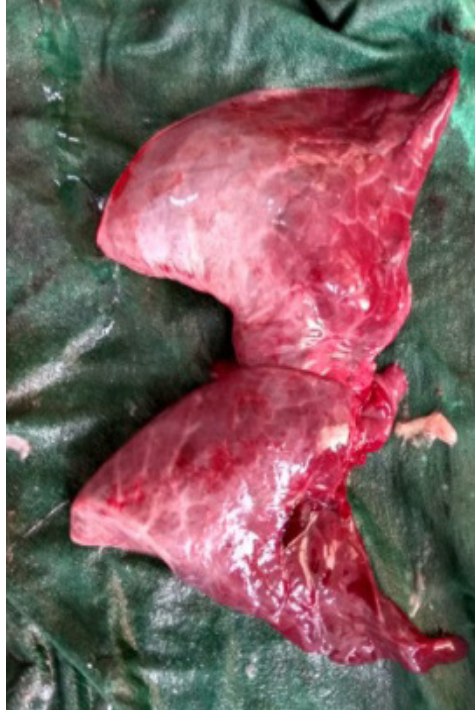

Figure 4. Congested fetal lungs.

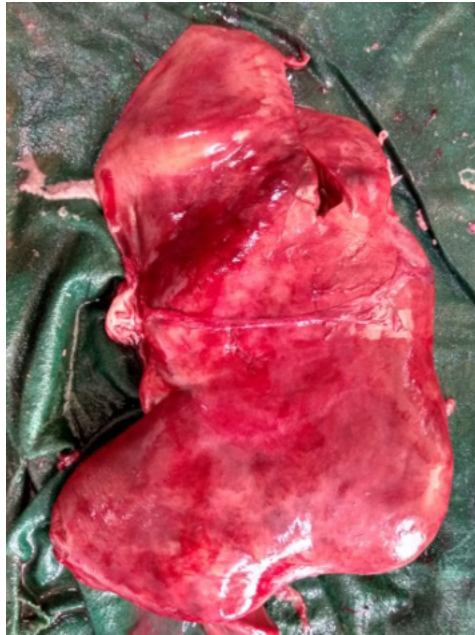

Figure 5. Fetal liver showing severe congestion.

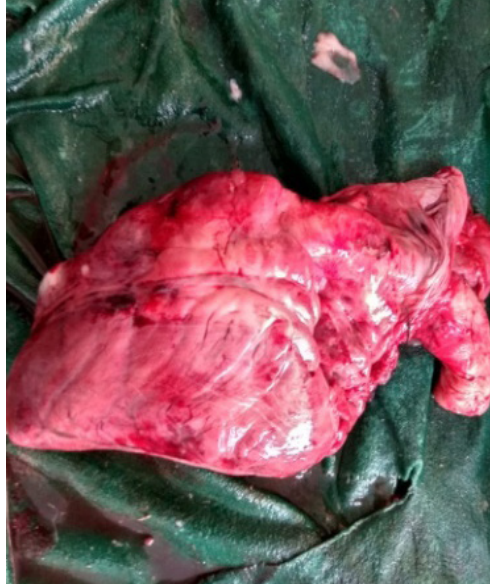

Figure 6. Heart showing severe congestion.

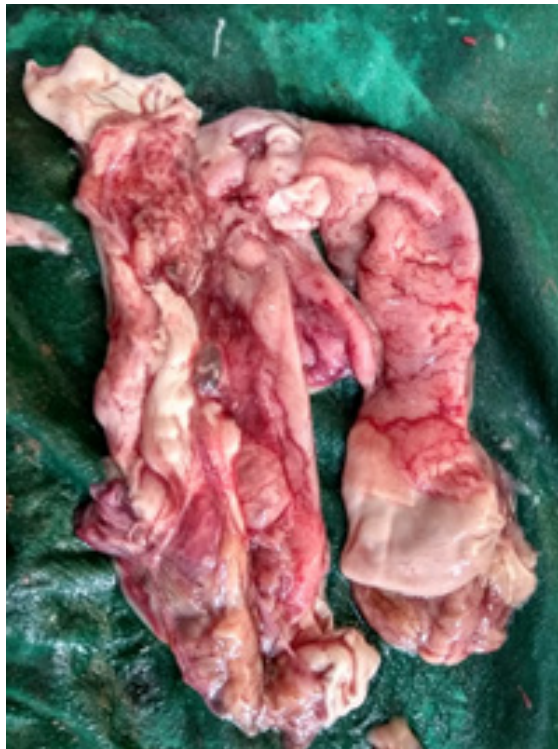

Figure 7. Rudimentary fibrous band like fetal brain.

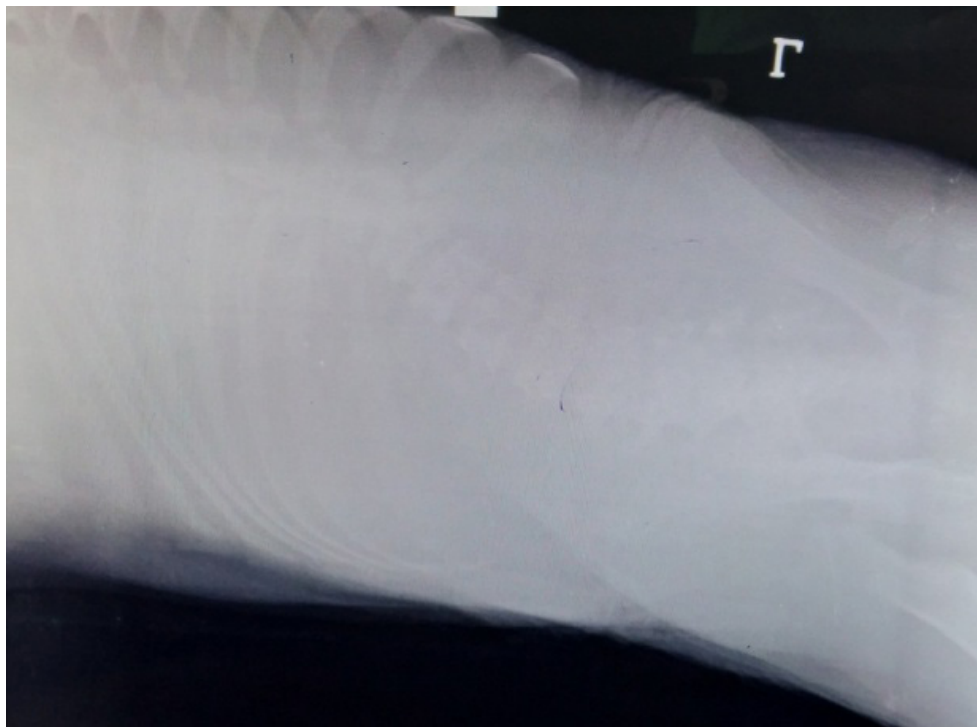


Figure 8. Radiographic image showing curvature of lumber vertebrates.

- Monstrosities in cows and buffaloes. *Indian Vet. J.*, **67**(11): 1042-1043.
- Jubb, K.V.F. and P.C. Kennedy. 1970. *Pathology of Domestic Animals*. Academic Press, New York, USA.
- Kumaresan, A., A. Garg and U.S. Mahapatra. 2003. Dystocia due to hydrocephalus in a buffalo calf. *Indian J. Anim. Reprod.*, **24**: 82.
- Noakes, D.E., T.J. Parkinson and G.C.W. England. 2019. *Veterinary Reproduction and Obstetrics*, 9th ed. Saunders, London, UK. 171p.
- Purohit, G.N., P. Kumar, K. Solanki, C. Shekhar and S.P. Yadav. 2012. Perspectives of fetal dystocia in cattle and buffalo. *Veterinary Science Development*, **2**(8): 31-42. DOI: 10.4081/vsd.2012.3712
- Roberts, S.J. 1971. *Veterinary Obstetrics and Genital Diseases (Theriogenology)*, 2nd ed. C.B.S. Publishers and Distributors, New Delhi, India. 60p.
- Salunke, S.P., M.B. Amle and P.C. Zambre. 2001. Dystocia due to hydrocephalus in Pantharpui buffalo. *Indian Journal of Animal Reproduction*, **22**: 96.
- Sharda, R. and S.P. Ingole. 2002. Congenital bilateral hydrocephalus in a Jersey cow calf: A case report. *Indian Vet. J.*, **79**(10): 965-966.
- Sharma, A. 1996. Dystocia due to hydrocephalic fetus with downward deviation of head in mare. *Indian Vet. J.*, **73**(3): 337-338.
- Szabo, K.T. 1989. *Congenital Malformations in Laboratory and Farm Animals*. Academic

Press, Inc. San Diego, California, USA.
313p.

Tripathi, A., J.S. Mehta, G.N. Purohit, S. Sharma, K. Saini and S.K. Pathak. 2014. Dystocia in a cow due to hydrocephalic fetus: A case report. *Journal of Livestock Science*, **5**: 79-82. Available on: <http://livestockscience.in/wp-content/uploads/dystocia-hydcep.pdf>

Upasana, R., G.R. Bhat, E.E. Varughese, S.P.S. Ghuman and M. Honparkhe. 2012. Per-vaginal delivery of a Murrah buffalo calf with congenital high-grade hydrocephalus internus. *Vet. Pract.*, **13**(2): 310-311.