

DESCENT OF GANGRENOUS UDDER TISSUE INTO THE TEAT CISTERN OF A MURRAH BUFFALO

Vandana Sangwan*, Himangshu Mazumdar, Ashwani Kumar and Ajaybir Singh Dhaliwal

ABSTRACT

The present case report describes successful surgical management of an unusual descent of gangrenous udder tissue into the teat cistern of a 15 year old non-gravid Murrah buffalo. The condition was one year chronic and the diameter and length of the left hind teat had gradually increased to 12.5 cm and 16 cm, respectively. On palpation teat was firm and non-painful. The B-mode ultrasonography showed presence of echogenic structure surrounded by hypo echoic contents within the teat cistern. Needle aspiration yielded pus. Surgical exploration revealed unusual descent of gangrenous udder tissue into the teat cistern, which was successfully managed.

Keywords: *Bubalus bublis*, buffalo, necrotic, amputation, bovine, udder affections, ultrasonography

INTRODUCTION

Affections of udder (4.2%) and teat (2.51%) are common in buffaloes with udder fibrosis and abscesses contributing upto 4 and 16%, respectively (Rambabu *et al.*, 2011). *Staphylococcus aureus* is

the most prevalent causative agent of mastitis in bovine (Baloch *et al.*, 2011; Haque *et al.*, 2013). Gangrenous udder is a common form of mastitis in bovine and small ruminants affecting the udder within 24 to 48 h of infection. Initially, the udder and teat is hot and painful which further develops into cold with discolored skin at some point, and eventually leads to abscess/pus formation (Ribeiro *et al.*, 2007). Usually, such animals are subjected to radical mastectomy for the removal of gangrenous quarter (Cable *et al.*, 2004). The present case was unusual, as no signs of gangrenous mastitis were ever shown by the buffalo, though the milk production of the affected quarter was nil since one year. The definite diagnosis of the present case was made on surgical exploration. The gangrenous udder tissue was found in the teat cistern, while the udder quarter was empty. So, the present case study puts on record a rare incidence of descent of gangrenous udder tissue into the teat cistern of a Murrah buffalo and its surgical management.

CASE HISTORY AND OBSERVATIONS

A 15 year old non-gravid Murrah buffalo weighing 560 kg was presented to the Department of Veterinary Surgery and Radiology with an

enlarged left hind teat (Figure 1). The condition was one year old and was gradually increasing in size. The buffalo had no milk production in both the teats of left side since then. The other side was normal, with approximate milk production of 15 liters/day. The only concern of the owner was to relieve the buffalo from the pain and uncomfortable behavior due to enlarged teat while sitting. The buffalo was non-cooperative for clinical examination in standing position due to unfamiliar surroundings, so mild sedation using inj. xylazine hydrochloride 0.08 mg/kg was given intramuscularly. The buffalo was restrained on the operation table for clinical examination. The teat was firm on palpation but, no inflammation, pain or gangrenous signs were observed. Mild discoloration at the tip of the teat was seen. B-mode ultrasonography revealed an echogenic structure surrounded with hypoechoic contents within the teat cistern (Figure 2). Needle aspiration yielded pus. Suspecting, it to be an abscess, surgical drainage was advised.

TREATMENT AND DISCUSSION

Surgical drainage of the contents of teat was done under local anesthesia using 2% lignocaine hydrochloride infiltrated as ring block. A lateral longitudinal skin incision was given on the affected teat and nearly, 100 ml of pus was drained through it. Finger palpation through the incision suspected fibrous tissue in the teat cistern. The incision was dorsally extended upto 10 cm and the palpable tissue was pulled out (Figure 3). The mass was identified as gangrenous udder tissue with fibrous meshwork. The annular sphincter at the base of the teat was palpated for remnants. The gland cistern was empty and the sphincter was only one finger open. The mucosa of the teat cistern

was thickened with linear folds on it (Figure 3). The cistern was thoroughly washed using normal saline and povidone iodine. The incision site was bleeding so a continuous layer of silk sutures (No. 2) was applied involving mucosa and skin of each side separately (Figure 4). Post operatively inj. Ampicillin-Cloxacillin 10 mg/kg and inj Gentamicin 2 mg/kg, twice daily, intramuscularly, was administered for 5 and 3 days, respectively along with inj. Meloxicam 0.2 mg/kg, once daily, for 3 days. Antiseptic dressing was advised using powder magnesium sulphate and a fly repellent spray. The skin sutures were removed 15th day post-operatively. On long term telephonic follow up, the teat size got reduced to near normal.

Mastitis is a common condition in bovine, directly affecting the farmer's economy (Riberio *et al.*, 2007; Rambabu *et al.*, 2011). Gangrenous mastitis is a dreadful condition of bovine udder. Gangrenous mastitis, in relation to milk production, bear poor prognosis, as after treatment the milk production is rarely restored. Gangrenous mastitis has been well documented in goat and cattle but in buffaloes it is not reported. Usually, gangrenous mastitis is diagnosed with its typical signs of initial udder and teat inflammation followed by cold with discoloration at some point, leading to rupture and draining pus in goat (Riberio *et al.*, 2007) and cattle. Scanty literature is available on the clinical signs of gangrenous mastitis in buffalo. The present case was unusual, as no typical signs were ever shown by the buffalo; secondly the descent of whole udder tissue into the teat cistern has not been reported in literature. Amputation of udder or radical mastectomy is reported to be specific surgical procedure for this type of mastitis (Cable *et al.*, 2004; Venugopalan 2010, Kumar *et al* 2012). Since, the present case was diagnosed on exploratory teat surgery and udder tissue was

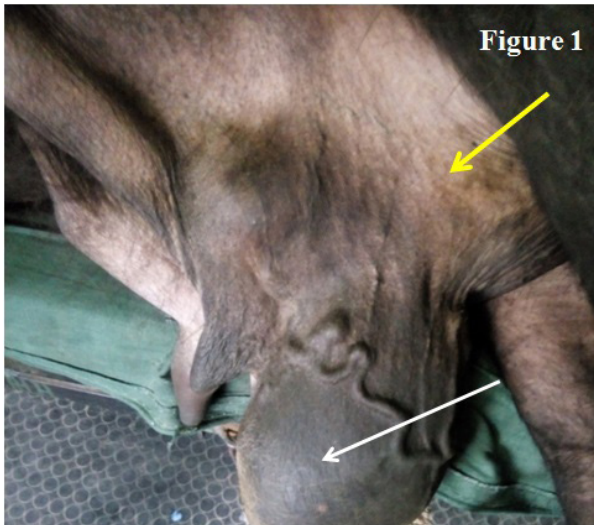


Figure 1. Photograph showing enlarged left hind teat (white arrow) and collapsed udder quarter (yellow arrow).

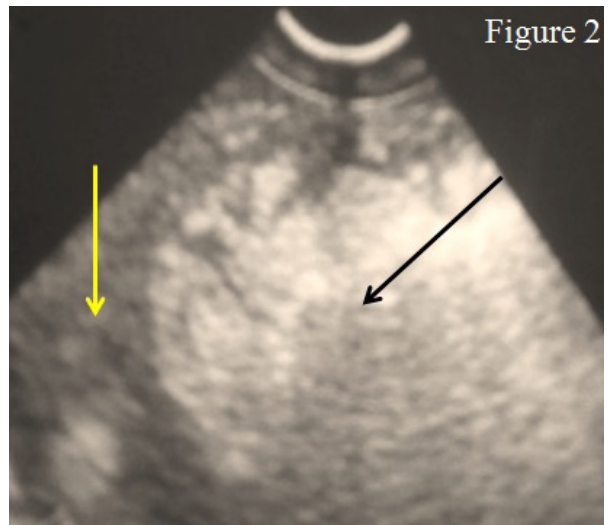


Figure 2. Ultrasonogram showing an echogenic structure (black arrow) surrounded with hypoechoic contents (yellow arrow) in the teat cistern.

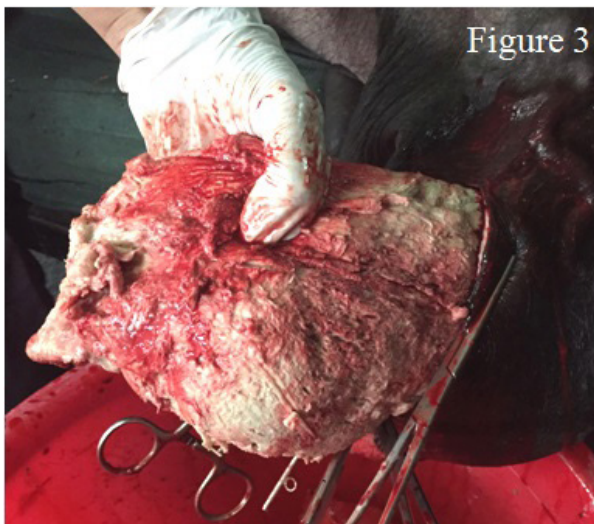


Figure 3. Photograph showing removal of gangrenous udder tissue from the left hind teat cistern.

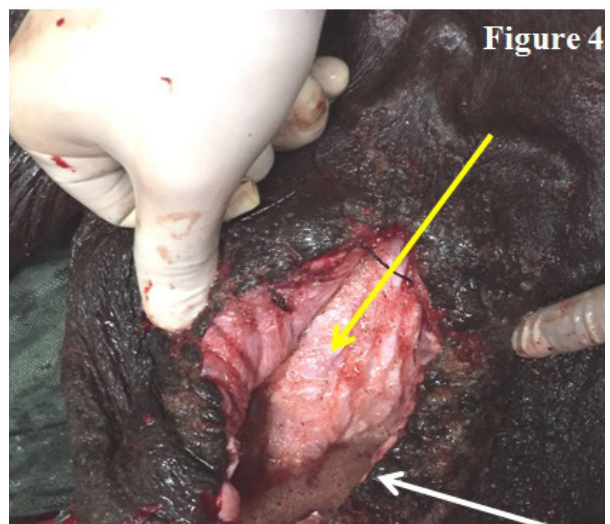


Figure 4. Photograph showing thickened teat cistern mucosa (yellow arrow) and sutured incised wall (white arrow).

easily removed from the teat cistern, leaving a clean wound, amputation was not advised.

In healthy adult buffalo, the average teat diameter and length is reported to be 2.76 ± 0.02 cm and 7.81 ± 0.15 cm, respectively (Prasad *et al.*, 2010). But in the present study it was markedly enlarged to 12.5 cm and 16 cm, respectively; however, the corresponding udder quarter was empty. The teat enlargement, despite no milk production, was related to the presence of gangrenous udder tissue in it which was confirmed on surgical exploration. Teat cistern dilatation due to wrong milking methods has been reported in buffaloes (Borghese *et al.*, 2007., Abd-El-Hady 2015), however, some authors attribute this condition as a congenital defect in dairy cows and refer it as 'bottle teat' or 'teat hyperplasia' (Nouh *et al.*, 2014).

REFERENCES

- Abd-El-Hady, A.A.A. 2015. Clinical observations on some surgical udder and teat affections in cattle and buffaloes. *Scholars Journal of Agriculture and Veterinary Sciences*, **2**(4A): 270-281.
- Baloch, H., R. Rind, D.H. Kalhoro and A.B. Kalhoro. 2011. Study on the incidence of clinical mastitis in buffaloes caused by bacterial species. *Pakistan Journal of Agriculture, Agricultural Engineering and Veterinary Sciences*, **27**(1): 83-93.
- Borghese, A., M. Rasmussen and C.S. Thomas. 2007. Milking management of dairy buffalo. *Ital. J. Anim. Sci.*, **6**(2): 39-50.
- Cable, C.S., K. Peery and S.L. Fubini. 2004. Radical mastectomy in 20 ruminants. *Vet. Surg.*, **33**(3): 263-266.
- Haque, S., S. Sahay, K.K. Singh and B.K. Roy. 2013. Bacteriology and antibiogram of bovine mastitis in ranchi and its vicinity. *Int. J. Agric. Sci. Vet. Med.*, **1**(1): 1-6.
- Kumar, A., S.K. Mahajan, K. Singh, V. Sangwan, M. Chandra, N.S. Saini and A. Anand. 2012. Unilateral mastectomy for the management of chronic suppurative mastitis in a goat. *Indian Journal of Small Ruminants*, **18**(1): 148-151.
- Nouh, S.R., A.S. Korittum., M.H. Elkammar and W.M. Barakat. 2014. Retrospective study of teat surgical affections in dairy farms of armed forces and their treatment. *Alexandria Journal of Veterinary Sciences*, **40**: 65-76.
- Prasad, R.M.V., E.R. Rao, K. Sudhakar, B.R. Gupta and M. Mahender. 2010. Studies on udder and teat measurements as affected by parity and their relationship with milk yield in Murrah buffaloes. *Buffalo Bull.*, **29**(3): 194-198.
- Rambabu, K., M. Sreenu, R.V. Sureshkumar and T.S.C. Rao. 2011. Incidence of udder and teat affections in buffaloes. *Tamil Nadu Journal of Veterinary and Animal Sciences*, **7**(6): 309-311.
- Ribeiro, M.G., G.H.B. Lara, S.D. Bicudo, A.V.G. Souza, T. Salerno, A.K. Siqueira and J.S. Geraldo. 2007. An unusual gangrenous goat mastitis caused by *Staphylococcus aureus*, *Clostridium perfringens* and *Escherichia coli* co-infection. *Arq. Bras. Med. Vet. Zoo.*, **59**(3): 810-812.
- Venugopalan, A. 2010. *Operative Surgery in Essentials of Veterinary Surgery*. Oxford and IBH Publishing Co. Pvt. Ltd., New Delhi, India. 501p.