

OCULAR SQUAMOUS CELL CARCINOMA: A PATHO-MORPHOLOGICAL AND AGNOR BASED DIAGNOSIS

**Shafiqur Rahman^{1,*}, Satuti Sharma¹, Nawab Nashiruddullah¹, Shilpa Sood¹,
Kafil Hussain², Rabiya Javed³ and Riya Abrol¹**

Received: 01 January 2022

Accepted: 21 June 2024

ABSTRACT

A fifteen years old female buffalo was referred to the Teaching Veterinary Clinical Complex (TVCC), RS Pura, Jammu, India with a history of purulent discharge and protruded mass from the right eye with an impaired vision for 30 days. On physical examination, there was ulcerated vesicular growth at the sclera corneal junction. Protruded mass was removed surgically and was taken for histopathological examination and AgNOR count. On histopathological studies, cells displayed severe anaplasia, pleomorphism, hyperchromatic nuclei, multiple nucleoli, and frequent mitotic figures and it was diagnosed as ocular squamous cell carcinoma. The value of mean and proliferative AgNOR for ocular squamous cell carcinoma was found to be 2.83 ± 0.87 and 32%, respectively. Based on patho-morphological examination and AgNOR count, the protruded mass was led to the final diagnosis of ocular squamous cell carcinoma.

Keywords: *Bubalus bubalis*, buffaloes, AgNOR count, eye tumour, squamous cell carcinoma, histopathology

INTRODUCTION

Buffaloes play a vital role in dairy developments programs in developing countries like India. Ocular squamous cell carcinoma (eye tumour/ cancer) is a very common and of great economic importance by causing carcass condemnation at slaughterhouses, shortened productive life with impairment of vision. The average age of bovine with this neoplasm is eight years and above. The tumours are not common in animals younger than five years and are rare in animals less than one year. Approximately 75% of the cases were involving the bulbar conjunctiva and cornea, and the remaining 25% were found equally distributed in the conjunctiva of the eyelids and membrane nictitans and skin of the lid (Moulton,

¹Division of Veterinary Pathology, Faculty of Veterinary Sciences and Animal Husbandry, Sher-e-Kashmir University of Agricultural Sciences and Technology of Jammu, Jammu, India,
*E-mail srahmanskuastj@gmail.com

²Division of Veterinary Medicine, Faculty of Veterinary Sciences and Animal Husbandry, Sher-e-Kashmir University of Agricultural Sciences and Technology of Jammu, Jammu, India

³Division of Veterinary Microbiology, Faculty of Veterinary Sciences and Animal Husbandry, Sher-e-Kashmir University of Agricultural Sciences and Technology of Jammu, Jammu, India

1990). The etiology for this tumour is variable and multifactorial which include heredity, sunlight, sunlight exposure for long hours, nutrition, eyelid pigmentation, and virus involvement (Rajmani *et al.*, 2012).

In general, the majority use of AgNOR as a proliferating assay has been studied in canine and feline tumours. To our knowledge, this is the first report of estimation of AgNOR count in squamous cell carcinoma of eye in buffalo. Thus, this present report communicates a case of ocular squamous cell carcinoma in a buffalo which was treated successfully by surgical interventions and histopathology and AgNOR count was also done for its confirmation and analysis of malignancy status.

MATERIALS AND METHODS

A fifteen years old female buffalo was referred to the Teaching Veterinary Clinical Complex (TVCC) SKUAST-Jammu, India with a history of purulent discharge and protruded mass from the right eye with an impaired vision for 30 days. On physical examination, there was ulcerated vesicular growth at the sclera corneal junction (Figure 1). Feed and water intake were normal. Heart, pulse, and respiration rates were normal. Even urination and defecation were also normal. Initially, the course of treatment of animal included topical application of eye drop and parental administration of antibiotic for the last 10 to 15 days but the animal did not show any significant improvement. Then growth was decided to be removed with proper sedation and with proper asepsis. The growing mass was removed by surgery and preserved in 10% formaldehyde solution and processed by routine

paraffin embedding method (Bancroft and Gamble, 2002). After staining with routine hematoxylin and eosin (H&E) stain, lesions were recorded. AgNOR study was conducted on these specimens used for histopathology and stain with slight modifications as per the method described by Crocker *et al.* (1989) and then visualized in 100 X using oil immersions under the microscope (Sharma *et al.*, 2021). AgNORs were seen as dark stain black-brown dots/foci clustered in the nucleus of neoplastic cell. For counting AgNOR, 100 cells were selected and variation in their size was also recorded. The mean AgNORs (mAgNOR) was achieved by dividing total count with 100 neoplastic cells. Proliferative index (pAgNOR) was calculated as the nuclei (%) with ≥ 5 AgNOR dots per nucleus in 100 nuclei.

RESULTS AND DISCUSSIONS

Before starting the surgery, the animal was sedated with xylazine intravenously according to the body weight and with proper regional nerve block using 2% lignocaine hydrochloride. After that growth was removed with proper asepsis condition (Figure 2) and post-operative measures were taken with antibiotic gentamicin according to the bodyweight intramuscular for 5 days and eye ointment application in affected eye for 10 days. The animal was fully recovered within a few days and thereafter no complication has been reported. The collected surgical mass was taken for studies of histopathology and AgNOR count.

Grossly, removed mass was hard, ulcerated, and vesicular present at the sclera-corneal junction of the right eye. On histopathological examination, there were anaplasia, pleomorphism, hyperchromatic nuclei, multiple nucleoli, and frequent mitotic figures seen (Figure 3). Pugliese *et*

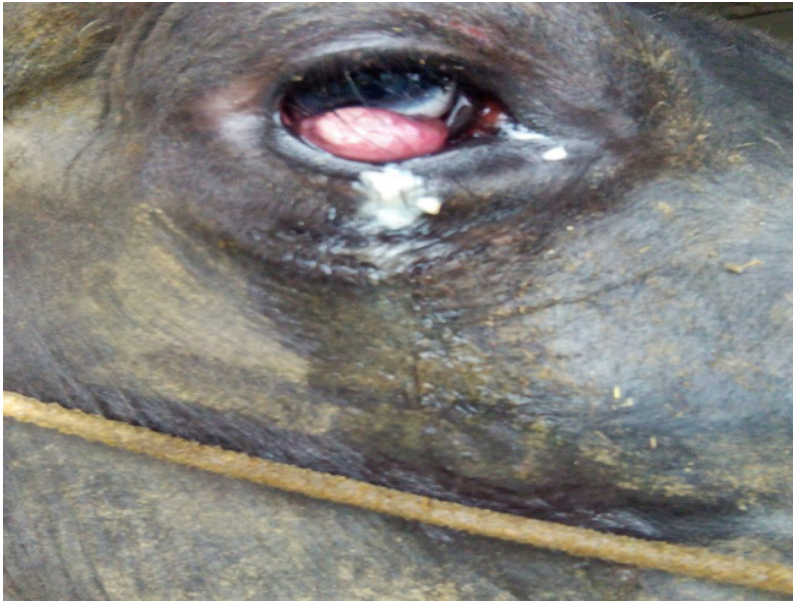

Figure 1. Protruded, ulcerated mass at the sclera corneal junction.

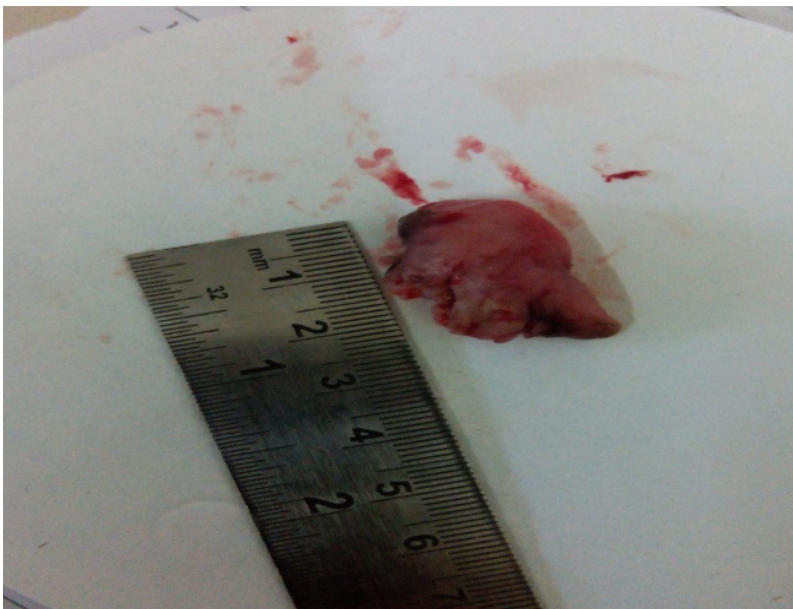

Figure 2. After removal the mass from the eye.

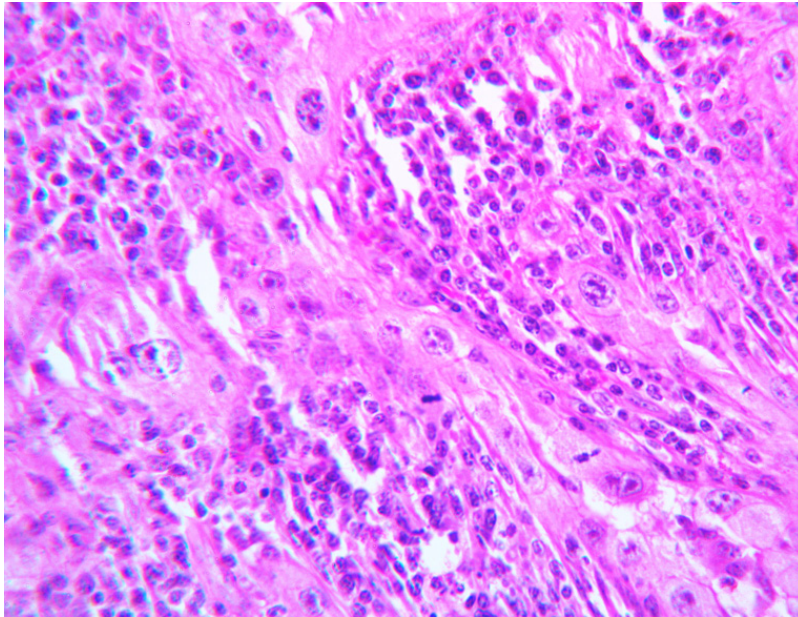


Figure 3. A poorly differentiated ocular squamous cell carcinoma showing anaplasia and pleomorphic cells with hyperchromatic nuclei and multiple nucleoli. Note the presence of frequent mitotic figures. H&E X400.

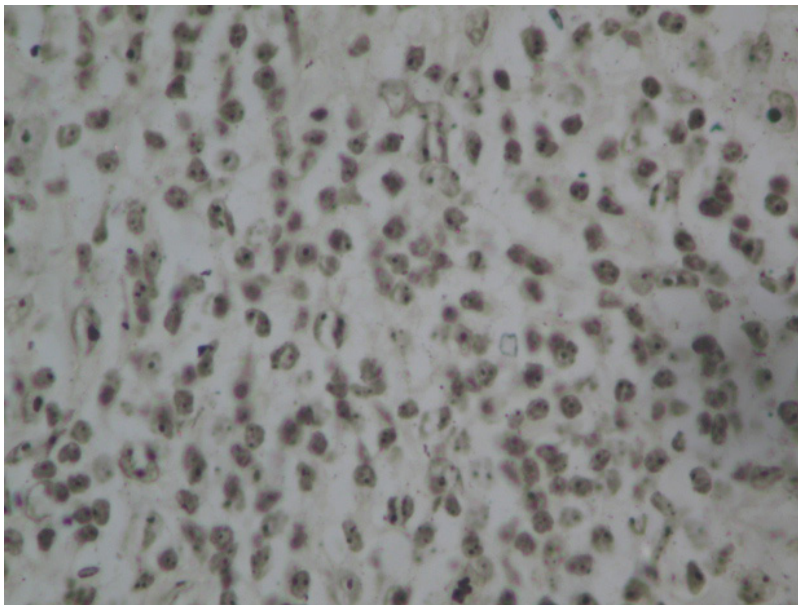


Figure 4. Ocular squamous cell carcinoma- irregular small AgNOR dots were visualized AgNOR X400.

al. (2014) noticed ocular squamous cell carcinoma in cattle with similar gross and histological findings. The gross and histological changes observed in the present study were described by Jubb *et al.* (1993); Jones *et al.* (1997); and Moulton (1990). Kalirajan and Kumar (2016); Soujanya and Kharde (2016) also observed the squamous cell carcinoma in the eye of crossbred cow and bullock, respectively. Similarly, Prasad and Samatha (2013); Tiwari *et al.* (2016) also reported ocular squamous cell carcinoma in buffaloes with alike gross and histopathological findings observed in the present case.

AgNOR staining showed the presence of numerous irregular shaped small black-brown dots within the nuclei of the neoplastic cells (Figure 4). The value of mAgNOR and pAgNOR was found to be 2.83 ± 0.87 , and 32%, respectively in the ocular squamous cell carcinoma. These findings agree with those of Mosunic (2003) who reported that AgNOR score as a proliferative assay was able to distinguish between different types of squamous cell carcinoma of eyes in equines. However, no case in literature is available suggesting the use of AgNOR for the diagnosis of ocular squamous cell carcinoma in buffalo. In humans, AgNOR have been often used as diagnostic aid and prognostic marker of squamous cell carcinoma particularly in the oral cavity but no study to date has used AgNOR count to evaluate ocular squamous cell carcinoma in buffalo. Sandhya *et al.* (2011) observed large irregular AgNOR dots or bizarre clusters in malignant tumours of oral cavity (squamous cell carcinoma). Similarly, Gulia *et al.* (2011) reported the value of mAgNOR of 3 grades of oral squamous cell carcinoma as 4.71 ± 0.81 , 6.34 ± 0.89 , and 8.70 ± 0.65 in human. The number of AgNOR per cell is closely related to the degree of cell proliferation and an increase in the number is

an indication of increased proliferation which may be consistent with malignancy (Agarwal *et al.*, 2014). Benign tumours usually showed few, large, round and sharply defined AgNOR dots while malignant tumours had small, irregular AgNOR dots/foci (Chandrasekar and Lalitha, 1995).

REFERENCES

- Aggarwal, T., G. Sawke and N. Sawke. 2014. Application of AgNOR in distinction of non neoplastic and neoplastic endometrial lesions. *People's Journal of Scientific Research*, **8**(1): 23-27. Available on: [https://www.pjsr.org/Vol.%208\(1\)%20-%20January%202015/4%20Dr%20Tanvi%20Aggarwal.pdf](https://www.pjsr.org/Vol.%208(1)%20-%20January%202015/4%20Dr%20Tanvi%20Aggarwal.pdf)
- Chandrasekar, V. and P.S. Lalitha. 1995. AgNOR count as a marker in ethmoid carcinoma in bovids. *Vet. Rec.*, **137**(1): 24-25. DOI: 10.1136/vr.137.1.24
- Crocker, J., D.A. Boldy and M.J. Egan. 1989. How should we count AgNORS? Proposals for a standardized approach. *J. Pathol.*, **158**(3): 185-188. DOI: 10.1002/path.1711580303
- Gharagozlou, M.J., P. Hekmati and J. Ashrafihelan. 2007. A clinical and histopathological study of ocular neoplasms in dairy cattle. *Veterinary Archives*, **77**(5): 409-426.
- Gulia, S.P., E. Sitaramam and K.P. Reddy. 2011. The role of silver staining nucleolar organiser regions in lesions of oral cavity. *Journal of Clinical and Diagnostic Research*, **5**(5): 1011-1015. Available on: <https://www.jcdr.net/articles/pdf/1540/27%20-%203059.pdf>
- Jones, T.C., R.D. Hunt and N.W. King. 1997. *Veterinary Pathology*, 6th ed. Williams and Wilkins, Baltimore, USA. p. 345-871.

- Jubb, K.V.F., P.C. Kennedy and N.C. Palmer. 1993. *Pathology of Domestic Animals*, 4th ed. Academic Press, California, USA.
- Kalirajan, R. and S. Kumar. 2016. Ocular squamous cell carcinoma in a cross bred dairy cow. *International Journal of Science, Environment*, **5**(6): 4277-428.
- Mosunic, C.B. 2003. *Equine ocular cell carcinoma: Retrospective and diagnostic study*. M.Sc. Thesis, University of Georgia, Athens, Georgia.
- Moulton, J.E. 1990. *Tumours in Domestic Animals*, 2nd ed. University of California Press Berkeley and Los Angeles, California, USA.
- Prasad, B.C. and V.S. Samatha. 2013. Occurrence of ocular tumours in buffaloes. *Indo-American Journal of Agricultural and Veterinary Sciences*, **1** (2): 51-54.
- Pugliese, M., G. Mazzullo, P.P. Niutta and A. Passantino. 2014. Bovine ocular squamous cell carcinoma: A report of cases from the Caltagirone area, Italy. *Italy Veterinarski Arhiv*, **84**(5): 449-457.
- Rajmani, R.S., M. Mishra, P.K. Singh, A.P. Sahoo, A.K. Tiwari, J. Doley and G.V.P.P.S.R. Kumar. 2012. Common neoplasms in animals-An overview. *Journal of Animal Research*, **2**(2): 127-137.
- Sharma, S., S. Rahman, N. Nashiruddullah, S. Sood and R. Abrol. 2021. Patho-morphological and AgNOR based diagnosis of cutaneous squamous cell carcinoma in buffalo. *Buffalo Bull.*, **40**(1): 199-204.
- Soujanya, S. and K.R. Kharde. 2016. Surgical management of ocular squamous cell carcinoma in a bullock. *Intas Polivet*, **17**(2): 489-490. Available on: <https://www.cabidigitalibrary.org/doi/pdf/10.5555/20173137969>
- Tiwari, D.K., S. Saharan, S. Sharma, R.N. Choudhary, N. Sindhu, V. Jaglan and S. Potaliya. 2016. Ocular squamous cell carcinoma in a buffalo: A case report. *Buffalo Bull.*, **35**(1): 11-13. Available on: https://kukrdb.lib.ku.ac.th/journal/ BuffaloBulletin/search_detail/result/331328