

## LARYNGOTRACHEAOESOPHAGEAL COMPRESSION DUE TO GIANT BENIGN HYPERPLASTIC THYROID IN A JAFFARABADI BUFFALO

Vineet Kumar\*, Shruti Vora and Foram Asodiya

### ABSTRACT

This report describes a case of laryngotracheoesophageal compression due to giant benign hyperplastic thyroid in a Jaffarabadi buffalo and thyroidectomy to relieve from compressive symptoms. Physical, radiographical and ultrasonographical findings confirmed enlarged thyroid. Under sedation and local analgesia, total thyroidectomy was performed via cervical midline approach and excised thyroid was submitted for further histopathological examination. Animal had an uneventful postoperative course and recovered well. Grossly, excised thyroid was of 30 cm x 10 cm in size and 850 g of weight. Both the lobes of the thyroid gland were symmetrically enlarged and had meaty appearance. Benign hypertrophy and hyperplasia was reported on the histopathological report of surgical specimen.

**Keywords:** *Bubalus bubalis*, buffalo, benign hyperplastic thyroid, Jaffarabadi buffalo, thyroidectomy, radiography, ultrasonography

### INTRODUCTION

Thyroid hyperplasia, which can result

in benign enlargement of the thyroid gland, or goiter, is a common disease in humans (Abraham *et al.*, 2007), but less so in livestock (Ong *et al.*, 2014). Mild respiratory obstruction is common in patients with goiter (Tseng *et al.*, 1987). It is often asymptomatic, however, and may be detectable only by cervical soft-tissue radiography (Jauregui *et al.*, 1977). Severe tracheal compression because of hyperplastic thyroid is often slowly progressive (Tseng *et al.*, 1987). On review of the literature, acute tracheal compression and dyspnea due to benign cervical goiter has been found in humans (Tseng *et al.*, 1987; Melliere *et al.*, 1988; Shaha, 1990; Sajja *et al.*, 2006; Basoglu *et al.*, 2009; Sharma *et al.*, 2010; Bayhan *et al.*, 2014; Ito *et al.*, 2015) only, and that require surgical intervention (Testini *et al.*, 2012). This could be the first report to describe a case of laryngotracheoesophageal compression due to giant benign hyperplastic thyroid in a Jaffarabadi buffalo and thyroidectomy to relieve from compressive symptoms.

### MATERIALS AND METHODS

#### Animal

A 6 years old, female, Jaffarabadi buffalo was presented to our college hospital with chronic

dyspnea and dysphagia. These signs were present for 6 months and had recently increased and became more severe. On presentation animal had marked stridor, tachypnea and tachycardia. Her rectal temperature was 99.7°F and capillary refill time was less than 2 seconds. Her physical examination revealed that she had a significantly large transcutaneous soft tissue mass caudal to the pharynx which was compressing the trachea (Figure 1).

### **Radiographical examination**

Radiography was performed using a MULTIMOBIL 10 mobile X-ray system. Cervical area of the animal was exposed using factors of 50 mAs and 80 kVp at a film focal distance of 90 cm before and after drenching of 2:1 barium sulphate-sterile normal saline mixture. Exposed directview computed radiography cassette was subjected to computed radiography system for detailed study. Left lateral neck radiograph revealed a bilobed mass of soft tissue density in the thyroid area (Figure 2a) with tracheal compression and dorsally displaced oesophagus (Figure 2b).

### **Ultrasonographical examination**

Ultrasonography was performed using a CTS-3300V portable ultrasound. Hair over the thyroid area was clipped. The area was swabbed with alcohol to remove excess oil, and acoustic gel was applied. The area over the thyroid was examined using a 3.5 MHz convex transducer. Sonography revealed a diffuse decreased echogenicity and heterogeneous parenchyma of thyroid gland in the transverse plane (Figure 3).

### **Surgical treatment**

An intramuscular injection of 10 mg/

kg enrofloxacin and 0.5 mg/kg meloxicam was administered approximately one hour prior to surgery. The animal was sedated with an intravenous injection of 0.05 mg/kg xylazine hydrochloride and restrained in right lateral recumbency. Further, 20 ml of 2% lignocaine hydrochloride was linearly infiltrated around the proposed site of operation to achieve local analgesia and surgical site was prepared aseptically. A 15 cm longitudinal skin incision was made directly over obstructing mass and total thyroidectomy was meticulously performed via cervical midline approach (Figure 4). Antimicrobial treatment with enrofloxacin (5 mg/kg intramuscularly, once daily) was continued for 5 days. Analgesia was provided with meloxicam (0.2 mg/kg intramuscularly, once daily) for three days. The bandage was changed and the wound lavaged daily with sterile saline containing 0.1% povidone iodine solution till wound healing. Skin sutures were removed on the postoperative day 12. The long term outcomes of the animal was inquired by telephone contact with the owner.

### **Histopathological examination**

Surgically excised tissue sample was fixed in 10% neutral buffered formalin solution, dehydrated with a graded ethanol series, cleared in Xylene and embedded in paraffin wax. Sections were cut at 5  $\mu$  thicknesses, deparaffinized and stained with hematoxylin and eosin (H and E) for histopathological diagnosis.

## **RESULTS AND DISCUSSION**

Thyroidectomy alone was effective in relieving compressive symptoms. Animal had an uneventful postoperative course and recovered

well. Grossly, excised thyroid was of 30 cm x 10 cm in size and 850 g of weight. Both the lobes of the thyroid gland were symmetrically enlarged and had meaty appearance (Figure 5). Microscopically, intense hypertrophy and hyperplasia of epithelial cells lining thyroid follicles were observed. Follicles were irregular in size and shape, and contained varying amounts of eosinophilic and vacuolated colloid. Some follicles lacked colloid and collapsed (Figure 6a). Lining epithelial cells were columnar with deeply eosinophilic cytoplasm and small hyperchromatic nuclei. Follicles were lined by single or multiple layers of hyperplastic epithelial cells in most of the follicles (Figure 6b). There was no evidence of invasion, and mitotic figures were not evident.

Thyroid hyperplasia in animals is often clinically endocrinologically quiescent. It is relatively common in young calves, but seldom reported in adult cattle and usually of little clinical importance (Ong *et al.*, 2014). In human literature, reported risk factors of upper airway obstruction are intrathyroidal haemorrhage, tracheal collapse, laryngotracheal infection causing oedema, primary or metastatic thyroid malignancies and worsening of a medical illness (Melliere *et al.*, 1988; Miller *et al.*, 1990; Sajja *et al.*, 2006), however, aforesaid risk factors had been ruled out in our case. Laryngotracheal compression and upper airway obstruction because of benign hyperplastic thyroid has been reported in humans (Tseng *et al.*, 1987; Melliere *et al.*, 1988; Shaha, 1990; Sajja *et al.*, 2006; Basoglu *et al.*, 2009; Sharma *et al.*, 2010; Bayhan *et al.*, 2014; Ito *et al.*, 2015), however, such report is unusual in buffaloes as in this case. Upper airway obstruction resulting from laryngotracheal compression from hyperplastic thyroid can be a life-threatening situation, and requires urgent surgical intervention (Testini *et al.*, 2012).

Thyroidectomy is a common surgical option for the treatment of giant benign hyperplastic thyroid which causes severe airway obstruction (Veyseller *et al.*, 2010). In this case too, thyroidectomy alone was effective in relieving compressive symptoms in the immediate postoperative period and thereafter. In studied buffalo, histopathological examination revealed narrowing or obliteration of follicular lumina, reduction or absence of colloid, and hypertrophy and hyperplasia of follicular epithelial cells lining thyroid follicles. This is similar to what has previously been noted in camel (Yadegari, 2015). Histopathological findings are consistent with the diagnosis of benign hyperplastic thyroid.

In summary, the case of laryngotracheoesophageal compression due to giant benign hyperplastic thyroid in a Jaffarabadi buffalo and thyroidectomy to relieve from compressive symptoms was reported for the first time in the present study.

## ACKNOWLEDGEMENTS

We are thankful to the Director of Research, Junagadh Agricultural University (JAU), Junagadh, Gujarat and Dean, College of Veterinary Science and Animal Husbandry, JAU for providing facilities required for the study.

## REFERENCES

- Abraham, D., N. Singh, B. Lang, W.F. Chan and C.Y. Lo. 2007. Benign nodular goiter presenting as acute airway obstruction. *ANZ J. Surg.*, **77**: 364-367.
- Basoglu, M., G. Ozturk, B. Aydinli, M.I. Yildirgan, S.S. Atamanalp and F. Celebi.



Figure 1. Image showing enlarged transcutaneous mass caudal to the pharynx in a female Jaffarabadi buffalo.

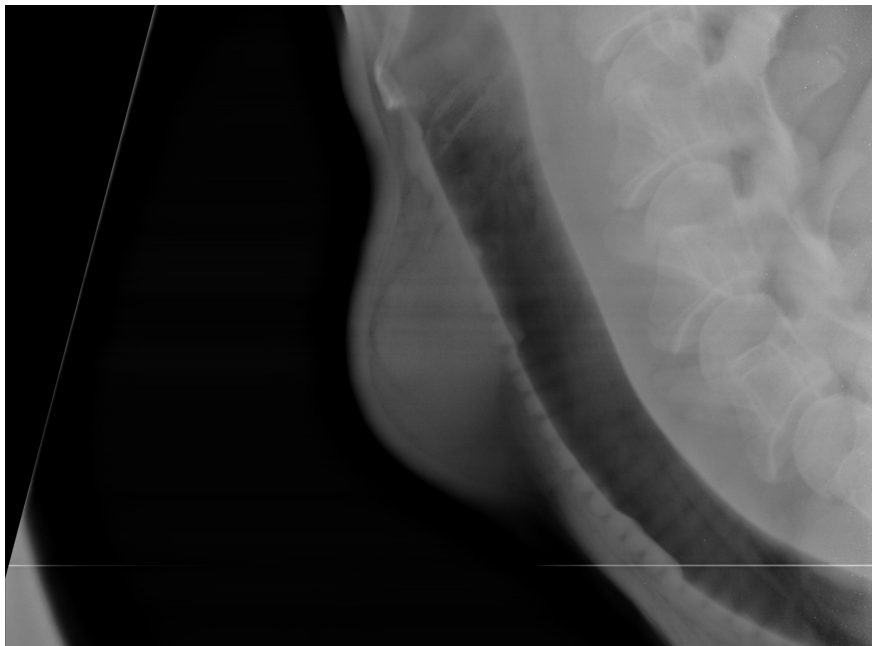


Figure 2a. Plain radiograph showing a bilobed cervical mass of soft tissue density.

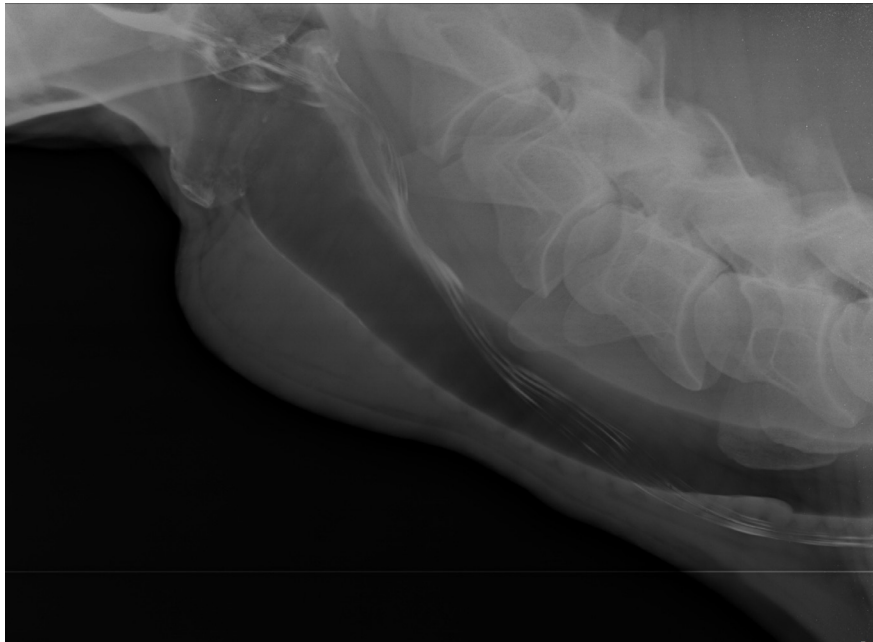


Figure 2b. Contrast radiograph showing a bilobed cervical mass of soft tissue density caudal to pharynx with tracheal compression and dorsally displaced oesophagus.

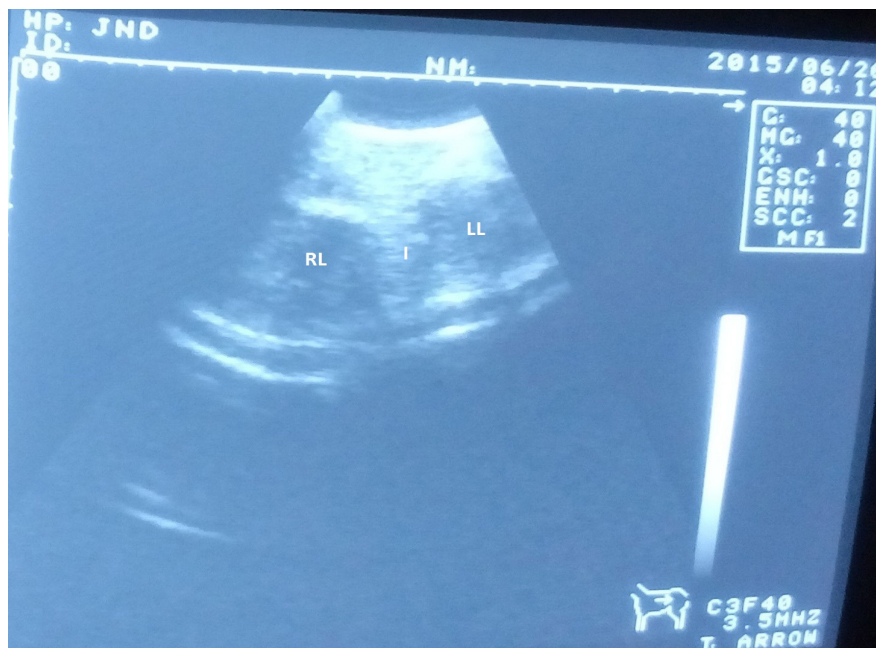


Figure 3. Sonogram showing a diffuse decreased echogenicity and heterogeneous parenchyma of thyroid gland. RL = Right lobe of thyroid gland; I = Isthmus; LL = Left lobe of thyroid gland.

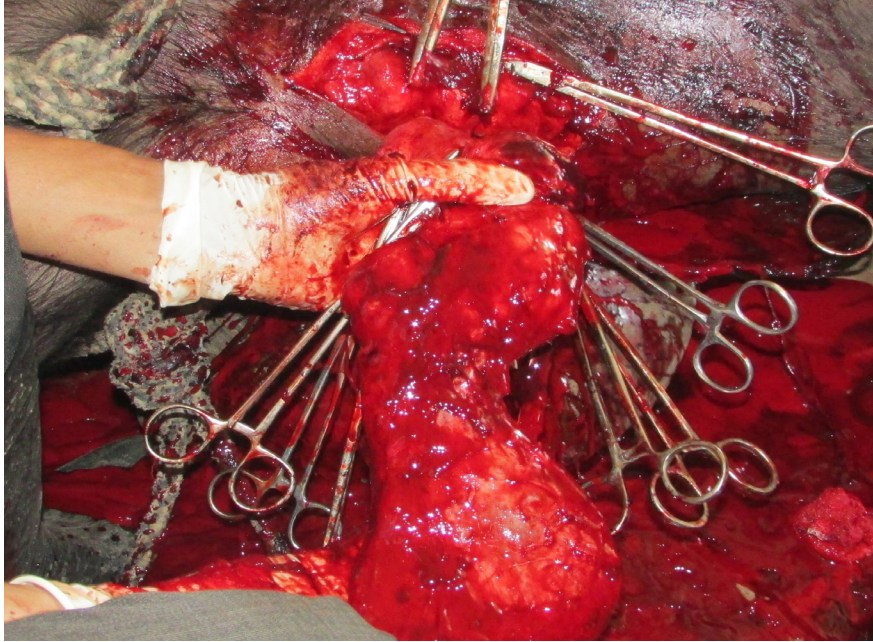


Figure 4. Intraoperative image showing enlarged thyroid gland.

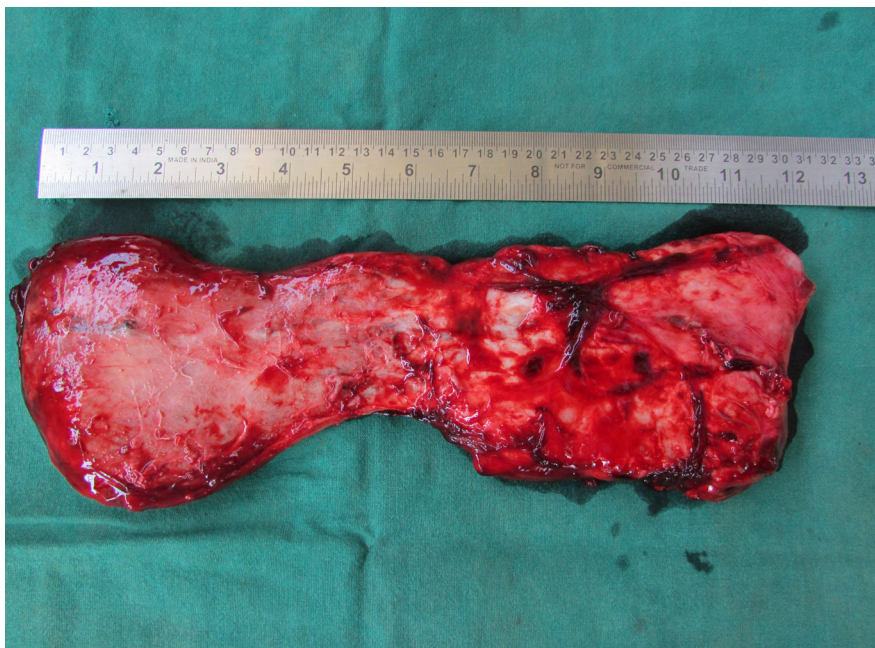

Figure 5. Excised thyroid of 30 cm x 10 cm in size with symmetrically enlarged lobes.

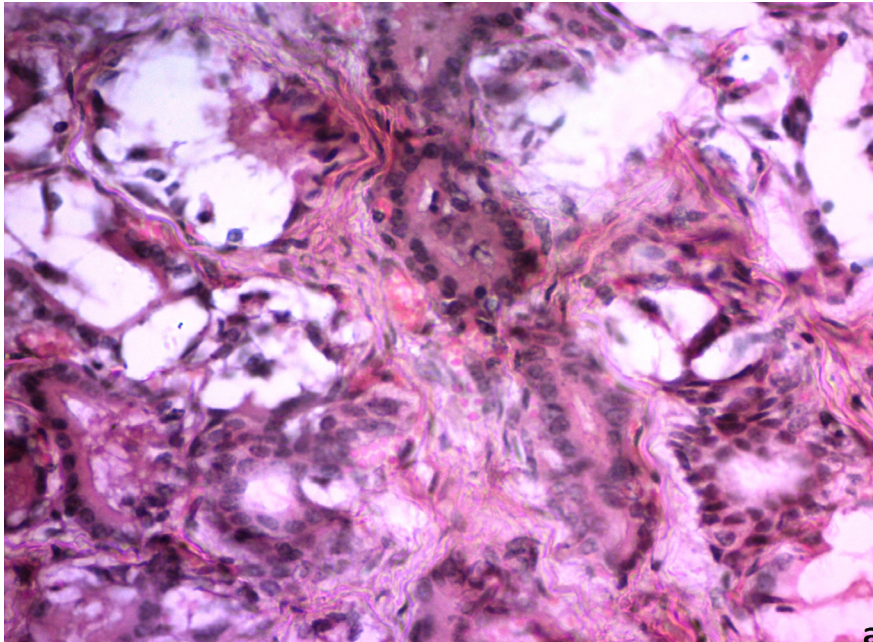


Figure 6a. Images of haematoxylin and eosin stained histological section of thyroid showing narrowing or obliteration of follicular lumina, reduction or absence of colloid (a), hypertrophy and hyperplasia of follicular epithelial cells lining thyroid follicles ( $\times 40$  magnifications).

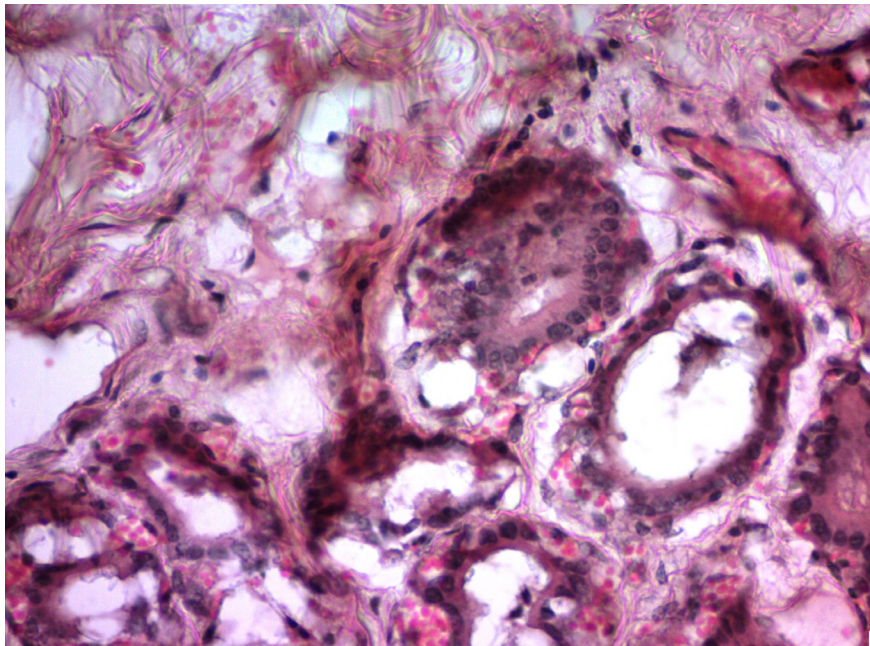


Figure 6b. Images of haematoxylin and eosin stained histological section of thyroid showing narrowing or obliteration of follicular lumina, reduction or absence of colloid (a), hypertrophy and hyperplasia of follicular epithelial cells lining thyroid follicles ( $\times 40$  magnifications).

2009. Benign nodular goiter causing upper airway obstruction. *The Eurasian Journal of Medicine*, **41**: 75-79.
- Bayhan, Z., S. Zeren, B.I. Ucar, I. Ozbay, Y. Sonmez, M. Mestan, O. Balaban, N.A. Bayhan and M.F. Ekici. 2014. Emergency thyroidectomy: Due to acute respiratory failure. *Int. J. Surg.*, **5**: 1251-1253.
- Ito, T., K. Shingu, C. Maeda, M. Kitazawa, Y. Mizukami, M. Hiraguri, N. Horigome, G. Kaneko, N. Itoh and K. Ito. 2015. Acute airway obstruction due to benign asymptomatic nodular goiter in the cervical region: A case report. *Oncol. Lett.*, **10**: 1453-1455.
- Jauregui, R., E.S. Lilker and A. Bayley. 1977. Upper airway obstruction in euthyroid goiter. *J. Amer. Med. Assoc.*, **238**: 2163-2166.
- Melliere, D., F. Saada, G. Etienne, J.P. Becquemin and F. Bonnet. 1988. Goitre with severe respiratory compromise: Evaluation and treatment. *Surgery*, **103**: 367-373.
- Miller, M.R., A.C. Pincock, G.D. Oates, R. Wilkinson and H. Skene-Smith. 1990. Upper airway obstruction due to goiter: Detection, prevalence and results of surgical management. *Q. J. Med.*, **74**: 177-188.
- Ong, C.B., T.H. Herdt and S.D. Fitzgerald. 2014. Hyperplastic goiter in two adult dairy cows. *J. Vet. Diagn. Invest.*, **26**: 810-814.
- Sajja, L.R., G.C. Mannam, S. Sompalli, C.S.R. Simhadri and A. Hasan. 2006. Multinodular goiter compressing the trachea following open heart surgery. *Asian Cardiovascular and Thoracic Annals*, **14**: 416-417.
- Shaha, A.R. 1990. Surgery for benign thyroid disease causing tracheoesophageal compression. *Otolaryng. Clin. N. Am.*, **23**: 391-401.
- Sharma, A., V. Naraynsingh and S. Teelucksingh. 2010. Benign cervical multi-nodular goiter presenting with acute airway obstruction: A case report. *Journal of Medical Case Reports*, **4**: 258.
- Testini, M., F. Logoluso, G. Lissidini, A. Gurrado, G. Campobasso, R. Cortese, G.M. De Luca, I.F. Franco, A. De Luca and G. Piccinni. 2012. Emergency total thyroidectomy due to non traumatic disease. Experience of a surgical unit and literature review. *World J. Emerg. Surg.*, **7**: 9.
- Tseng, K.H., J.V. Felicetta, L.L. Rydstedt, D.G. Bouwman and J.R. Sowers. 1987. Acute airway obstruction due to a benign cervical goiter. *Otolaryngology-Head and Neck Surgery*, **97**: 72-75.
- Veyseller, B., F. Aksoy, Y.S. Yildirim and H. Demirhan. 2010. Emergency thyroidectomy. *J. Surg. Arts*, **1**: 9-11.
- Yadegari, M. 2015. Evaluation of prevalence of the types of thyroid disorders using ultrasound and pathology of one humped camel in Iran (*Camelus dromedarius*). *Int. J. Agr. Biol. Eng.*, **9**: 154-157.