Original Article

Buffalo Bulletin (July-September 2026) Vol.45 No.3
https://doi.org/10.56825/bufbu.2026.4535536

RADIOLOGICAL FEATURES OF STIFLE IN PRENATAL AND POSTNATAL STAGES OF BUFFALO (*Bubalus bubalis*)

Bharath Kumar Magge Lokesh*, Pramod Kumar Dammaraju and Rajendranath Nalla

Received: 27 July 2023
Accepted: 06 July 2026

ABSTRACT

Anatomically the stifle joint comprises of three articulations *viz*, femorotibial, femoropatellar and proximal tibiofibular of which the former two are important diarthrodial articulations. Femorotibial joint is the largest joint in the body comprising two paired condyloid articulations between condyles of femur and corresponding tibial condyles. Radiographic features of the stifle joint in the present study showed secondary ossification centres for distal and proximal epiphyses of femur and tibia respectively were not seen in radiographs of 161 days old fetus (CVRL 39.1 cm), but it appeared as a faint spot in 165 days fetus (CVRL 40.6 cm) in Group 1. The tibial plateau was well developed but was not yet fully ossified in Group 3. In animal aged approximately more than six years anterior posterior view radiograph showed a thin rim of articular cartilage covering the femoral and tibial condyles. They were completely ossified by their respective shafts in Group 4.

Keywords: *Bubalus bubalis*, buffaloes, stifle joint, radiograph, prenatal stage, postnatal stage

INTRODUCTION

Buffalo plays a significant role in agricultural economy of several tropical countries including India where it occupies a unique position amongst livestock (Singh *et al*., 1963). Conventional radiography is an excellent imaging technique for bony structures and for investigation of morphologic changes in bones. Areas that can be evaluated by radiography are subchondral bone plates, articular margins, areas where ligaments, tendons, joints attach. In humans and horses joint space narrowing is well accepted indicator of articular cartilage degeneration (Gielen*et al*., 2012).Lameness has been major problem faced by the in-buffalo farming where in most cases has root of it, which hinders the economical by the way of decreased milk yield or semen production in she buffalo or he buffalo in respective cases. Hence thorough knowledge of radiological features of stifle is aimed at this study.

MATERIALS AND METHODS

Intact stifle joint specimens of twenty-four apparently healthy buffaloes and fetuses were

Department of Veterinary Anatomy, College of Veterinary Sciences, Rajendranagar, Hyderabad, India, *E-mail: bkml608@gmail.com

procured from either hind limb by a cut at the level of distal and proximal thirds of femur and tibia respectively. Aging of the post natal specimens was done by carefully noting the dentition pattern of the slaughtered animals as per FAO (1994) and employing Soliman formula (1975) for prenatal age estimation. The collected specimens were divided into four groups such as Group 1 (Prenatal), Group 2 (young 0 to 3 years), Group 3 (3 to 6 years) and Group 4 (>6 years).

Soon after collection the specimens were first cleaned with wet cloth to remove blood stains and pressed firmly to drain excess fluids after which they were taken for X ray exposure for radiological observations in latero-medial view (LV) and anterior-posterior view (APV) for studying anatomical details and also for other features like developmental status of the components of the stifle joint and the findings were recorded.

RESULTS AND DISCUSSIONS

Group 1

Secondary ossification centres for distal and proximal epiphyses of femur and tibia respectively were not seen in radiographs of 161 days old fetus (CVRL 39.1 cm), but it appeared as a faint spot in 165 days fetus (CVRL 40.6 cm). It later became a distinct spot in radiographs of 168 days fetus (CVRL 41.8 cm). Distal epiphysis of femur appeared as a distinct spot in LV and APV radiographs in 168 days fetus (CVRL 41.8 cm). These are similar toradiographic observations of secondary ossification centres of distal epiphysis of femur at 163 days of gestation in bovines by Lindsay (1969) and in 170 days buffalo fetus by Dhilleswara (2011). In other animals it was noticed by radiography at 42 days of gestation in sheep (Harris, 1937), 85 days old fetal pig (Wrathall *et al*., 1974) and between 93 to 105 days in sheep fetus (Wenham, 1981) which indicated that distal epiphysis of femur appeared mostly in 1st trimester of gestation in domestic animals. In the LV and APV radiographs of specimen aged 226 days (CVRL 67.6 cm) the distal extremity of femur increased in size and was opposed to the metaphyseal end of femur. This area pertained to the femoral condyles. Its cranial end showed sign of future trochlea taking shape, and a small patella was also observed (Figure 1). The metaphyseal ends of distal and proximal ends of femur and tibia were wider at this stage. The tibial plateau was large and adjacent to the proximal metaphyseal end of tibia. Even at this stage the tibial tuberosity which develops separately was not seen. These observations are in agreement with the reports of Dhingra and Tyagi (1970) in goat fetuses who reported that five separate ossification centres for distal epiphysis of femur. In ox it appeared shortly before birth, was very distinct at 3 years and it fused with metaphysis at 3.5 years and above (Konig and Liebiech, 2004). In other animals it was seen at 85 days in foetal pig (Wrathall *et al*., 1974), at 265 to 300 days of gestation in horse (Getty, 1975), at 113 days sheep fetuses (Wenham, 1981) and at 117 days in goat fetus (Parmar *et al*., 2009) by radiography.

Dhingra and Tyagi (1970) reported four ossification centres for developing proximal epiphysis of tibia in goat fetuses, whereas Konig and Liebich (2004) recorded the appearance and fusion of ossification centre in proximal condyles of tibia of ox during mid 6th to 7th month of pregnancy.

Single centre of ossification for developing patella was evident in stifle joint radiographs taken in 226 days old buffalo fetus (CVRL 67.6 cm) which coincided with the statement of Burt *et al.* (1968) who mentioned that in ruminants patella

developed individually from a separate centre of ossification which was also endorsed by other author like in reports of Lindsay (1969) in 203 days old bovine fetuses and in 216 days buffalo fetus by Dhilleshwara (2011). Patella appeared at 120 days of gestation in sheep fetus (Harris, 1937).

Group 2

In anterior posterior view radiographs well-formed medial and lateral femoral condyle with a distinct intercondylar space was observed. Both condyles were almost entirely ossified with the distal end of femur except at a small area on their abaxial borders. Patella was noticed at the proximal part of the femoral trochlea.

Lateral view radiographs of the show the ossified part of the distal end of femur with its metaphyseal plate (Figure 3). Patella was also seen at the cranial end of the femoral trochlea. In this view the proximal end of the tibia (tibial plateau) was convex in shape but was separated from the anterior tibial tuberosity. The latter was formed from a different centre of ossification in the anterior part of the tibia (Figure 3). At this stage it did not ossify with the tibia.

The tibial plateau in anterior posterior view showed distinct tibial spine with pointed ends of the medial and lateral tibial condyles. The joint space and its contour appeared normal in freshly collected specimen one year old specimen with a thin rim of articular cartilage on articular ends of the bones involved in femorotibial articulation (Figure 2). In both the specimens shown in APV and LV radiographs the tibial plateau was ossified in most part with proximal end of the tibia except at its abaxial borders. Surface of respective lateral and medial tibial condyles were almost flat with slight concavity (Figure 3).

Group 3

The femoral condyles in stifle specimens of this group were almost completely ossified when seen in flexed AP view radiograph (Figure 4). Their shape was convex and covered by a thin layer of articular cartilage. The intercondyloid fossa observed was receiving the tibial spine. In lateral view the same specimen patella was observed on the cranial aspect of the distal end of trochlea of femur. The ridges of the trochlea were visible clearly. Straight patellar ligaments at the anterior part of the joint were also noticed (Figure 5). They stretched from patella to the anterior tibial tuberosity. The joint space was clear with articular cartilage covering the articulating condyles (Figure 4).

The tibial plateau was well developed but was not yet fully ossified. A clear line separated it from the proximal end of tibia. Both the tubercles of the spine were clear and pointed opposing the intercondylar fossa of femur in anterior posterior view radiographs of (Figure 4). Tibia is the tibial tuberosity, and crest was clearly outlined even at this age *i.e.*, three to six years age (Group 3), the tibial tuberosity was still separate at the anterior proximal end of tibia as observed in lateral view radiographs (Figure 5).

Group 4

In animal aged approximately more than six years anterior posterior view radiograph showed a thin rim of articular cartilage covering the femoral and tibial condyles (Figure 7). They were completely ossified to their respective shafts. In lateral view radiograph patella was observed on the cranial aspect of the distal end of trochlea of femur. The tibial plateau was well developed and fully ossified to the tibial metaphysis (Figure 7 and 8). Tubercles of the spine on tibial plateau

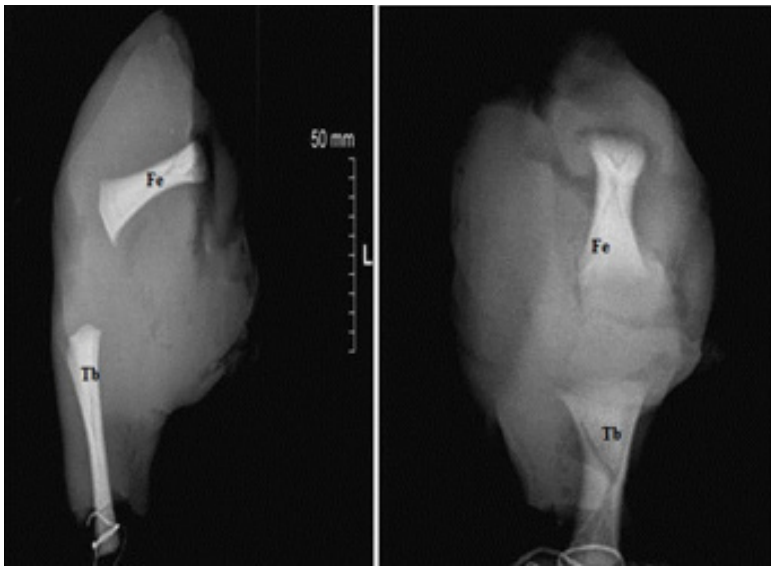

Figure 1. Lateral and Antero-posterior radiographs of stifle joint of Group 1 specimen aged 161 days (CVRL 39.1 cms) showing shafts of femur and tibia Fe- Femur, Tb- tibia.

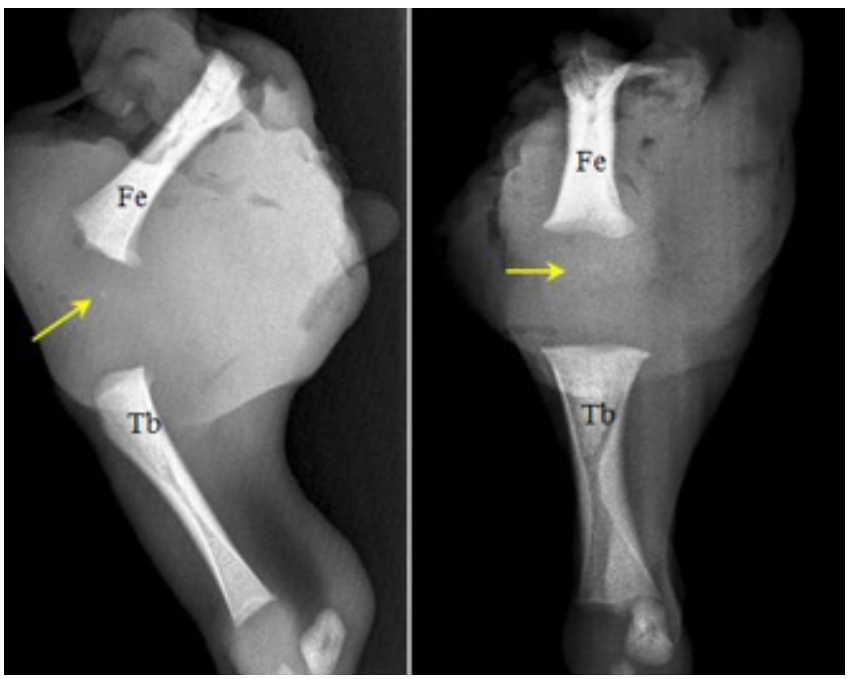

Figure 2. Lateral and Antero-posterior radiographs of stifle joint of Group 1 specimen aged 165 days (CVRL 40.6 cms) showing small faint spot (arrow) at the distal extremity of femur. Fe- Femur, Tb- tibia.

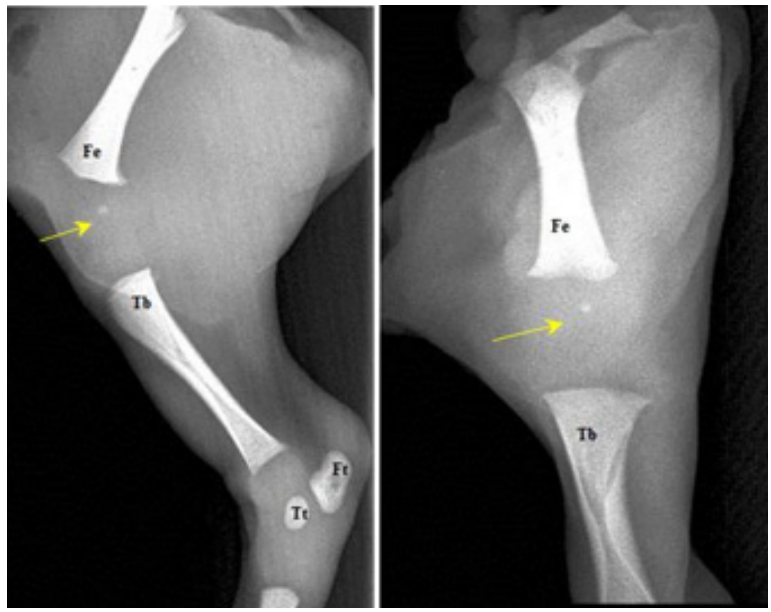

Figure 3. Lateral and Antero-posterior radiographs of stifle joint of Group 1 specimen aged 168 days (CVRL 40.6 cms) showing distinct small spot in the vicinity of distal end of femur. Fe- Femur, Tb- tibia.

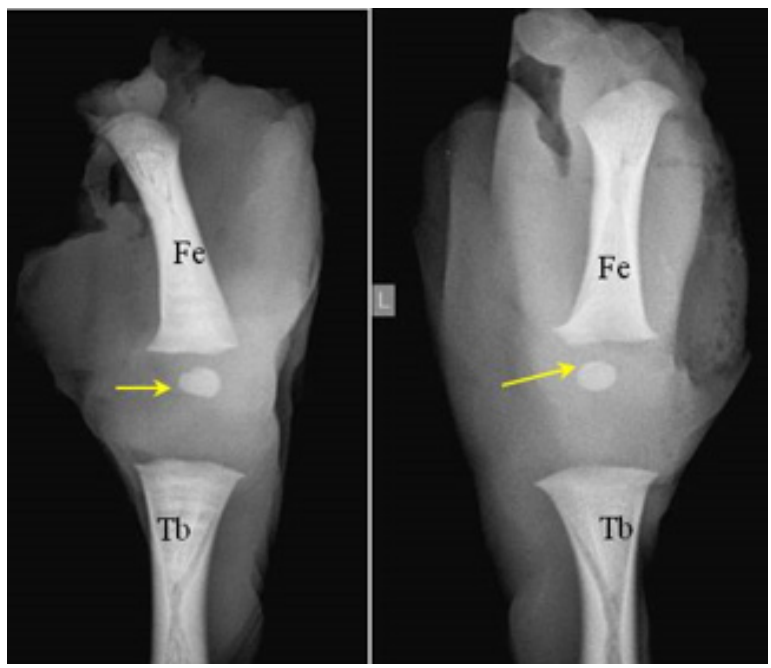

Figure 4. Antero-Posterior radiographs of stifle joint of Group 1 specimens aged 180 days (CVRL 47.5 cms) showing large oval spot of developing distal extremity of femur. Fe- Femur, Tb- tibia.

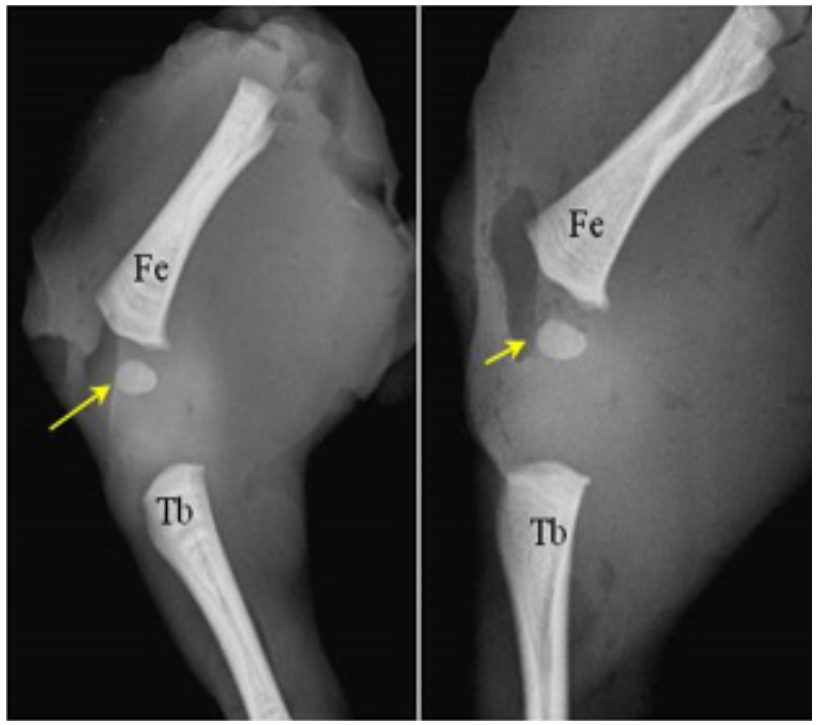

Figure 5. Antero-Posterior radiographs of stifle joint of Group 1 specimens aged 189 days (CVRL 51.2 cms) showing large oval spot of developing distal extremity of femur. Fe- Femur, Tb- tibia.

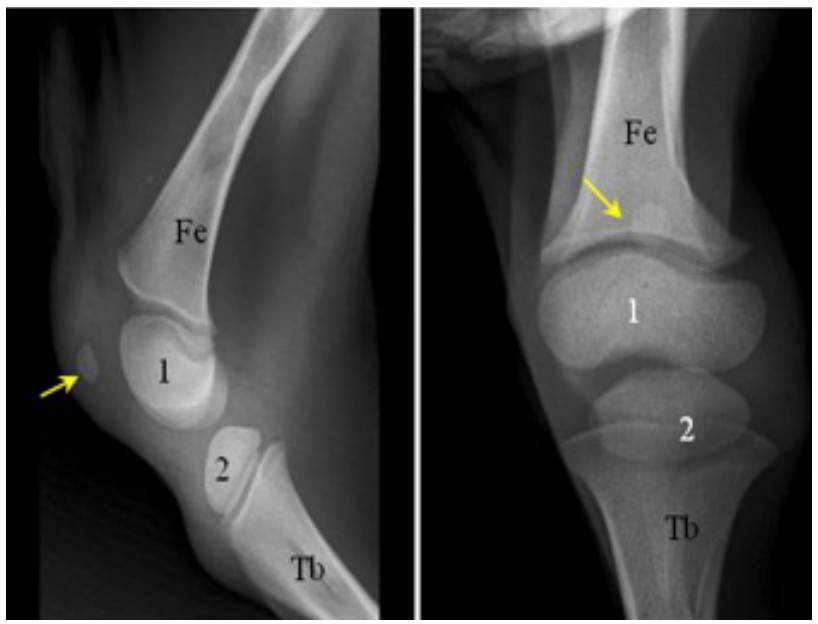

Figure 6. Lateral and Antero-posterior radiographs of stifle joint of Group 1 specimen aged 226 days (CVRL 66.7 cms) showing large developed distal (1) and proximal extremities of femur and tibia (2). Fe- Femur, Tb- tibia.

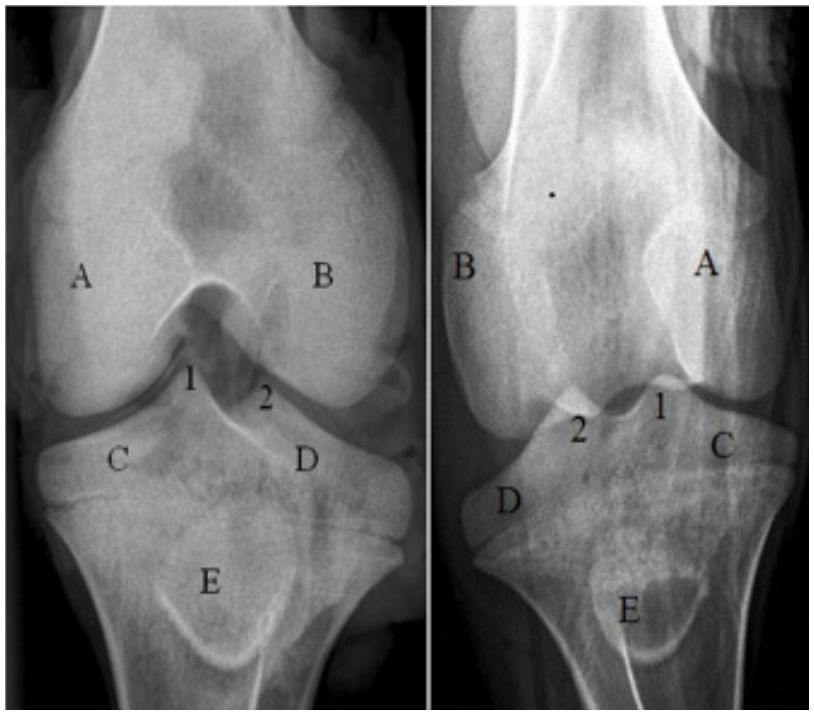

Figure 7. Antero-Posterior radiographs radiographs of one fresh stifle joint (left) and one formalin fixed specimen (right) of Group 2 showing anatomical details of the joint. A and B: condyles; 1 and 2: tubercles, C and D: tibial plateau E Tuberosity.

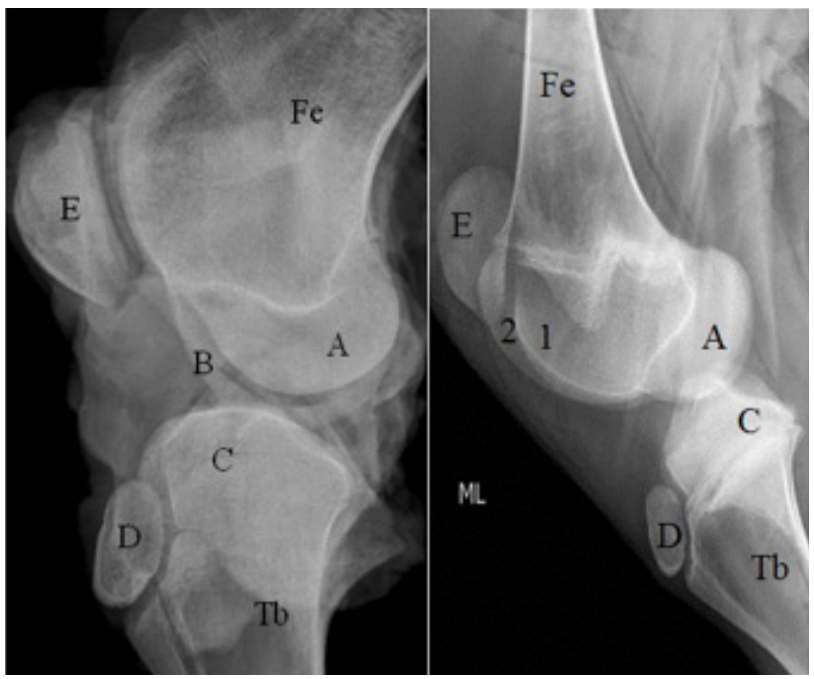

Figure 8. Lateral radiographs of one fresh stifle joint (left) and formalin fixed specimen (right) of Group 2 showing anatomical details of the joint. Fe: femur, Tb: tibia, A and B: condyles, 1 and 2: trochlear ridges; D: Tuberosity.

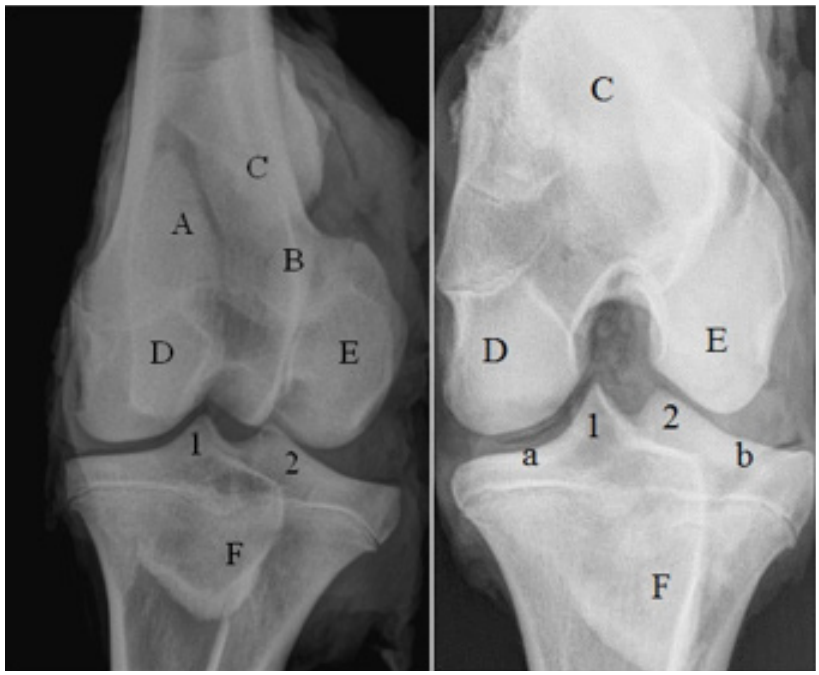

Figure 9. Antero-posterior radiographs of stifle joint of Group 3 specimen in normal position (left) and in a flexed position (right) showing anatomical details, A and B: trochlear ridges; C: Patella; D and E: Condyles; 1 and 2: tubercles, F: Tuberosity.

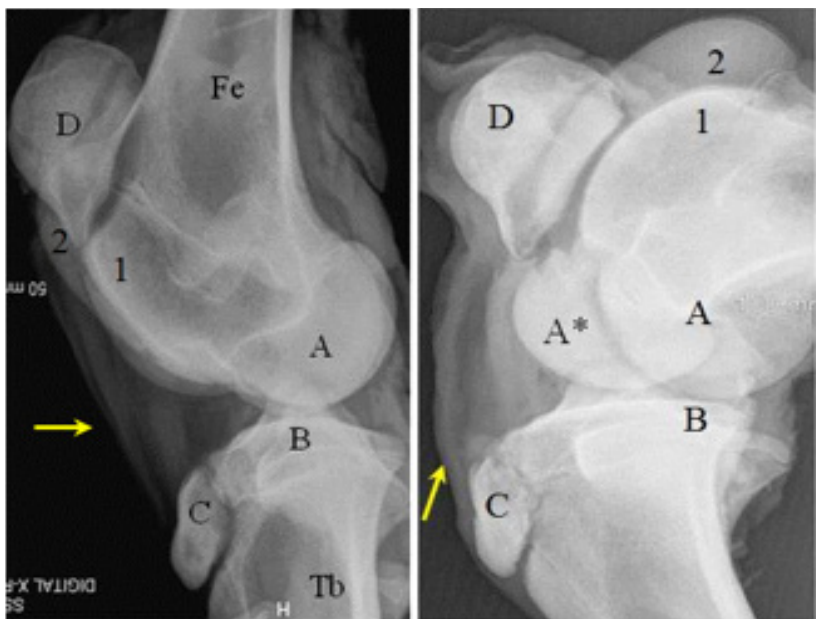

Figure 10. LV radiographs of stifle joint of Group 3 specimen in normal position (left) and in a flexed position (right) showing anatomical details. Fe: Femur; Tb: tibia A; A* and B: Condyles; 1 and 2: trochlear ridges; C: Tuberosity; Arrow Showing Patellar Ligaments.

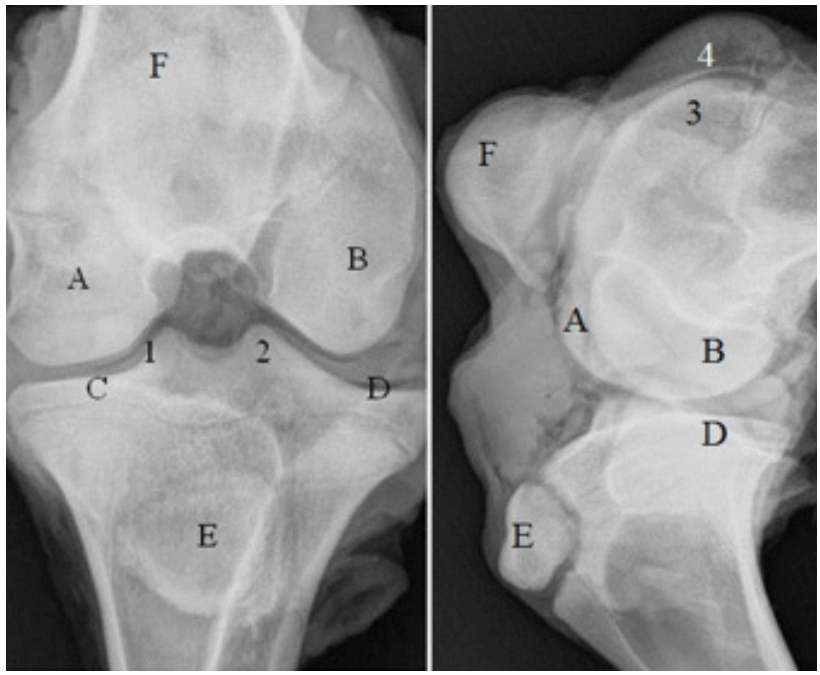

Figure 11. Antero-posterior and Lateral radiographs of stifle joint of Group 4 specimen aged around 6 ½ years showing anatomical details, A and B Condyles; 1 and 2: tubercles; 3 and 4: trochlear ridges; F: Patella; C and D: Tibial Plateau; E: Tuberosity.

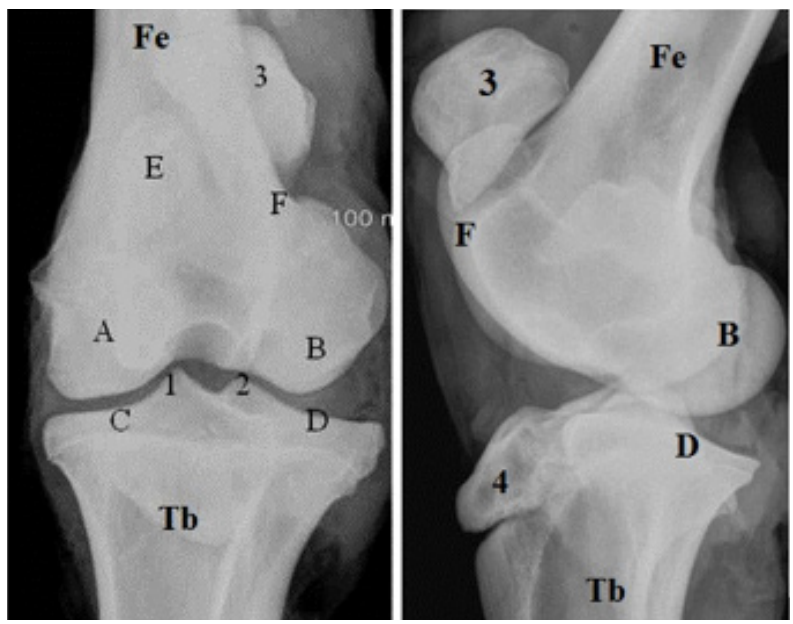

Figure 12. Antero-posterior and Lateral radiographs of stifle joint of Group 4 specimen aged around 7 years showing anatomical details and ossification of tibial tuberosity in proximo-distal direction to tibial plateau. Fe: Femur; Tb: Tibia; A and B: Condyles; C and D: Tibial Plateau; 1 and 2: tubercles; 3: Patella; E and F: trochlear ridges; 4: Tuberosity.

were clear and pointed opposing the intercondylar fossa of femur. Among the two, the medial spine was slightly at a higher level than its counterpart. In LV radiographs (Figure 7) the tibial tuberosity was still separate at the anterior proximal end of tibial plateau. Whereas in the LV radiographs of specimen in Figure 10 it was seen to be ossified in proximal to distal direction to the tibial plateau. Only a small lip-like gap was observed at the anterior most distal end of the tibial tuberosity.

CONCLUSION

Distal extremity of femur increased with advancing age which was noticed as a round dense spot in midpoint of the distal end adjacent to the area of metaphyseal plate in APV radiographs of 180 days fetus (CVRL 47.5 cm) and 189 days fetus (CVRL 51.2 cm at the level of the femoral condyles. At this stage ossification centres for proximal extremity of tibia which differentiates into condyles of tibial plateau were not visible. However, in stifle radiographs of specimen aged 226 days (CVRL 67.6 cm) well developed distal extremity of femur was seen opposed to the metaphyseal end. Its cranial end showed signs of future trochlea taking shape, and a small patella was also observed. At this stage the metaphyseal ends of distal and proximal ends of femur and tibia were wider and large tibial plateau was observed. Even at this stage tibial tuberosity was not seen.

In APV and LV radiographs of stifle regions of Group 2 prominent medial and lateral femoral condyles with distinct intercondylar space were observed. Both were almost entirely ossified with the distal end of femur except at a small area on their abaxial borders. Patella was noticed at proximal part of the femoral trochlea. Proximal end of the tibia (tibial plateau) was convex in shape but was separated from the anterior tibial tuberosity. The latter developed from a different centre of ossification in the anterior part of the tibia but was unossifed to tibial shaft.

A distinct tibial spine formed by medial and lateral tibial condylar eminences was seen in APV and LV radiographs which also showed the tibial plateau was ossified in most part with proximal end of the tibia except at its abaxial borders. Surface of respective lateral and medial tibial condyles were almost flat with slight concavity. Bony structures involved in the stifle joint formation developed in detail in Groups 3 and 4 wherein the femoral condyles were almost completely ossified and were convex shaped and lined by a thin layer of AC.

Intercondyloid fossa receiving the tibial spinewasvisible with developed patella and ridges of the trochlea. Straight patellar ligaments at the anterior part of the joint were also noticed which stretched from patella to anterior tibial tuberosity in stifles of Groups 3 and 4. Tibial plateau was well developed but was not yet fully ossified. A clear line separated it from the proximal end of tibia. Tibial tuberosity and crest were clearly outlined even at this age *i.e*., three to six years age (Group 3). Former was still separate at the anterior proximal end of tibia. In radiograph of one specimen of Group 4, (Figure 11 and Figure 12) stifle joint components were prominent and anterior tibial tuberosity was seen ossifying with proximal epiphysis of tibia in proximo-distal direction. Medial and lateral trochlear ridges were well developed showing the difference in thickness and size between them.

REFERENCES

Dhilleswara, R.S. 2011. *Prenatal development of*

appendicular skeleton of buffalo (*Bubalus bubalis*) M.V.Sc., Thesis Sri Venkateswara Veterinary University, Tirupati, India.

Dhingra, L.D. and R.P.S. Tyagi. 1970. A Study of the prenatal ossification centres and epiphyseal ossification in the limb bones of the goat. *Ceylon Veterinary Journal*, **18**(4): 111-118.

FAO. 1994. *Chapter 3: Cattle, sheep, goats and buffalo, Unit 9: How to age sheep, goats, cattle and buffalo*, Food and Agriculture Organization, Rome, Italy.

Getty, R. 1975. *Sisson and Grossman's The Anatomy of the Domestic Animals*, 5th ed. W.B. Saunders Company, Philadelphia, USA. p. 255-348.

Gielen, I., B.V. Ryssen and V.H. Bree. 2012. Diagnostic imaging of the canine stifle, p. 33-36. *In The 30th International Workshop for Small Animal Arthroscopy*, Merelbeke, Belgium.

Harris, H.A. 1937. The foetal growth of the sheep, *Journal of Anatomy*, **71**(4): 516-527.

Konig, H.E. and H.G. Liebich. 2004. *Textbook and Color Atlas of Veterinary Anatomy of Domestic Mammals*. Schattauer Publisher, Stuttgart, New York, USA. p. 197-228.

Lindsay, F.E. 1969. Observations on the loci of ossification in the prenatal and neonatal bovine skeleton. I. The appendicular skeleton. *Br. Vet. J.*, **125**(3): 101-111. DOI: 10.1016/S0007-1935(17)49057-9

Singh, S., O.P.S. Sengar and S.N. Singh. 1963. Prenatal development of buffalo (*Bos bubalis*). *Agra University Journal of Research*, **12**: 197-246.

Soliman, M.K. 1975. Studies on the physiological chemistry of allantoic and amniotic fluids of buffaloes at various periods of pregnancy. *Indian Vet. J.*, **52**: 106-111.

Wenham, G. 1981. A radiographic study of the primary and secondary ossification centres in the feotuses. *Journal of Agriculture Science*, **88**: 553-566.

Wrathall, A.E., Bailey and C.N. Hebert. 1947. A radiographic study of development of the appendicular skeleton in the fetal pig. *Res. Vet. Sci.*, **17**(2): 154-168.